

## Ebstein Anomaly in Pregnancy

*Lusiani Rusdi, Syahrir Azizi, Christopher Suwita, Astrid Karina, Sally A. Nasution*

Department of Internal Medicine, Faculty of Medicine Universitas Indonesia - Cipto Mangunkusumo Hospital, Jakarta, Indonesia.

**Corresponding Author:**

Sally A. Nasution, MD. Division of Cardiology, Department of Internal Medicine, Faculty of Medicine Universitas Indonesia- Cipto Mangunkusumo Hospital. Jl. Diponegoro no. 71, Jakarta 10430, Indonesia. email: sallynasution8@gmail.com; doclus78@gmail.com.

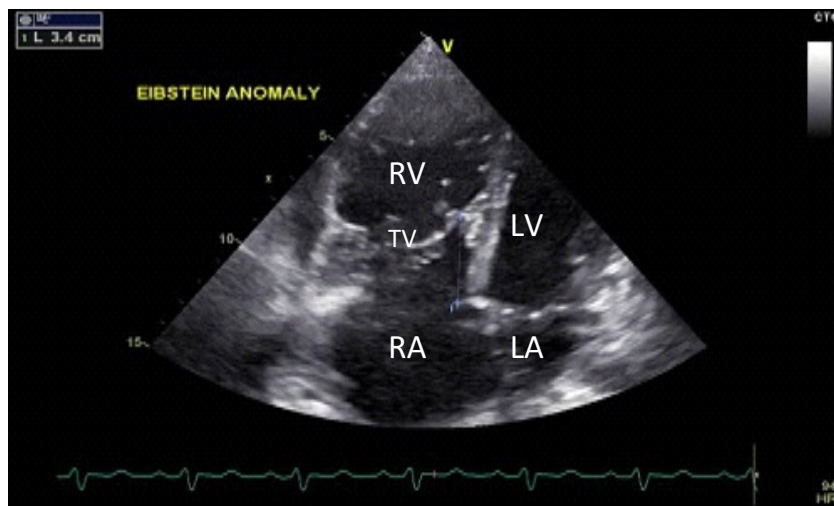


Figure 1.

Ebstein’s anomaly is a rare but fascinating congenital cardiac abnormality with various associated intra-cardiac anomalies. One of the most common associated anomalies is PFO or ASD. The increasing pulmonary blood flow through a PFO or ASD (left-to-right shunt) often leads to pulmonary hypertension. There are multifarious genetic factors in EA. Maternal lithium therapy and other environmental factors such as viral infections are may in rare cases lead to Ebstein’s anomaly.

A 27-year-old primiparous woman with 28 weeks gestational age was admitted to our hospital with worsening shortness of breath. She was diagnosed with Ebstein’s anomaly three years ago, but preferred to be left untreated. The

patient was not cyanotic and her vital signs were stable. Her ECG showed incomplete RBBB and prolonged PR-interval. Blood tests revealed mild anemia. Observation of two-dimensional echo with color flow Doppler study showed Ebstein’s anomaly with PFO as additional defects, EF of 57%, LV and LA dilatation, RV atrialization, severe TR, and moderate PH with RVSP of 44.3 mmHg. The patient then underwent elective sectio caesaria at 30 weeks of gestational age; both the mother and her baby were alive and were in good conditions. Problem: there was an increasing breathlessness in this patient so that there was an increasing need to take a decision for her pregnancy.

Ebstein's anomaly is a complicated congenital anomaly. Medical treatment may be followed for many years in patients with mild forms of Ebstein's anomaly. Surgery should be considered if there is objective evidence of debasement such as significant enlargement of heart size, reduction of systolic function in echocardiography.