

Primary Lymphoma of The Gastrointestinal Tract

Agus Sudiro Waspodo*, Kuku B. Rachmat**, Wirasmi Marwoto***, Ali Sulaiman*,
A.H. Reksodiputro****

*Department of Internal Medicine/Dharmas National Cancer Hospital

**Department of Surgery, Medical Faculty, University of Indonesia/Cipto Mangunkusumo National Centre Hospital Jakarta

***Department of Pathology Anatomy University of Indonesia/Cipto Mangunkusumo National Centre Hospital Jakarta

****Department of Internal Medicine, Medical Faculty, University of Indonesia/Cipto Mangunkusumo National Centre Hospital, Jakarta.

ABSTRACT

We report three rare cases of mucosal-associated lymphoid tissue (MALT) lymphoma. Two cases are of gastric MALT lymphoma and one is a case of transverse colon MALT lymphoma. The two cases of gastric MALT lymphoma were diagnosed by endoscopy which demonstrated an ulcer in the cardia and another in the corpus.

*The first case is in a 62-year-old male. The patient's medical history revealed upper GI tract bleeding with melaena in 1993. At the time no diagnosis was made on endoscopy. In August 2000, melaena recurred and endoscopy showed an ulcer in the cardia. Histology showed high-grade gastric MALT lymphoma. Based on Ann Arbor classification, the patient was classified as stage IE gastrointestinal lymphoma. *H. pylori* was negative. The patient received chemotherapy.*

*The second case is in a 53-year-old male. He suffered from gastric lymphoma for 3 years. He complained of annually recurring haematemesis before a definitive diagnosis was finally established. He suffered from stage IE low-grade well-differentiated lymphocytic MALT lymphoma. *H. pylori* was negative. Endoscopic procedure after *H. pylori* eradication showed ulcer regression though histology still showed low-grade MALT lymphoma and *H. pylori* as positive.*

The third case is in a 46-year-old male with a complaint of haematochezia. Colonoscopy showed intususception due to tumor in the transverse colon. Histologic examination showed chronic colitis and granulomatosa. Invagination due to colon tumor was reported. Histologic examination of the biopsy specimen showed low-grade small cell lymphocyte-plasmacytoid lymphoma.

Key words: Lymphoma, Helicobacter pylori, malignancy.

INTRODUCTION

The gastrointestinal tract is one of the largest immune organs of the human body. In the mucosa and submucosa of the intestines and colon, there are abundant lymphocytes and plasma cells that play a role in the body's immune system.¹ According to Dawson, primary lymphoma of the gastrointestinal tract is a lymphoma limited within the gastrointestinal tract or within the gastrointestinal tract and its closest lymph nodes when the diagno-

sis is made.²

The incidence rate for primary lymphoma of the gastrointestinal tract is not very high. Studies in Scandinavia and Scotland report an annual incidence rate of 1.5 cases in 100.000.^{3,4} Reports from Israel mention an annual incidence rate of 1 in 100.000.⁵

Hyperplasia of MALT as a response to chronic stimulation from ingested antigen is suspected to cause the production of a substance that could induce genetic mu-

tation towards neoplasia.⁶

This disease most commonly affects patients in their sixties and seventies, and is found least in patients less than 10 years of age.⁷

The standard diagnostic procedure includes history, physical examination, thoracic x-ray, blood count, liver function test, x-ray of the upper and lower gastrointestinal tract using contrast, and CT-scan or MRI of the abdomen and pelvis. Endoscopic examination is also necessary, and is preferable if done serially. Another important examination is lumbar puncture examination.⁸

Histopathologic examination using the light microscope is still the basis of diagnosis. Immunocytochemistry examination of tissue in paraffin is useful to determine the stem cell. Immunocytochemistry of frozen section could be used to differentiate B cell neoplasm from that of T cell phenotype. A study reported that 84% of primary lymphoma of the gastrointestinal tract is derived from the B cell, and only 8% is derived from the T cell.⁹

The therapy of choice for primary lymphoma of the gastrointestinal tract is still debateable. Five year life expectancy after curative resection is reported to reach 75% and only 32% in groups of patients who only underwent biopsies or palliative resection.¹⁰ A longer life expectancy rate is reported in stadium IE/IIIE patients who underwent complete resection.⁸

Post-operation radiation does not increase life expectancy.^{11,12} The benefit of post-resection radiation is felt in cases with residual disease after resection. Patients with less than 2.5 cm of residual lymphoma have a higher life expectancy rate after post-operation radiation compared to those with a residual tumor of 2.5-5.0 cm and those with more than 5.0 cm.¹³

Combined chemotherapy with or without radiotherapy increases life expectancy if utilized as an addition to resection.¹

A study demonstrated that 5 out of 6 MALT lymphoma cases demonstrated regression to the point of being undetectable after eradication of *H. pylori*.¹⁵

We report 2 cases of gastric maltoma out of 1463 gastroduodenoscopy and 1 case of maltoma of the transverse colon out of 364 colonoscopy from the year 1995 to 2000 at Pelni Petamburan Hospital.

CASE REPORT

Case I

A 62-year-old male was referred for gastroduodenoscopy with a chief complaint of melaena after taking methylprednisolone. The patient also com-

plained of epigastric discomfort, which was unrelated to meals.

Melaena had been a problem for this patient for 7 years before being hospitalized. Barium meal examination demonstrated duodenitis and duodenal ulcer. Gastroduodenoscopy at that time did not demonstrate any abnormality. Barium enema demonstrated a redundant colon. CEA serum tumor marker proved to be within normal limits.

Since then, the patient has been hospitalized several times.

The patient also suffered from hypertension and type II diabetes mellitus. For these conditions, the patient received norvask and amaryl.

Physical examination showed the patient to be mildly ill, anemic and without jaundice. The patient's blood pressure was 120/80 mmHg, his temperature was 36.8°C, and his pulse rate was 98 beats per minute. Heart and lung examination proved to be within normal limits. His abdomen was not enlarged, it was soft, there was no tenderness or tumor. His liver and spleen were not palpable. There was no edema or palmar erythema on the extremities. Lymph nodes were not palpable.

Laboratory results were as follows: hemoglobin level 12.7%, leukocyte count 11,000/mm³, LED 10 mm/hour, platelet count 253,000/mm³, Hematocrite 37%, SGOT 26 U/l, SGPT 22 U/l, γ GT 25 U/l, alkaline phosphatase 89 U/l, total bilirubin 0.58%, albumin 3.7%, globulin 2.1%, ureum 70 mg%, creatinine 1.0 mg%, cito blood glucose 167 mg%, blood in the urine ++.

Ultrasonographic examination of the upper abdomen revealed that it was within normal limits.

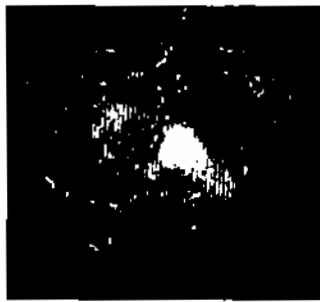
Gastroduodenoscopy showed an ulcer in the gastric cardiac region. The mucosa and fold were edematous and hyperemic (Figure 1.a.)

Histopathologic examination of the biopsy of the gastric cardiac region demonstrated an abundance of acute and chronic inflammatory cells. There were atypical lymphocytes with pleomorphic nucleus. There was also a lympho-epithelial lesion. Such histologic characteristics were in line with high-grade maltoma with the formation of ulcer and micro-abscess.

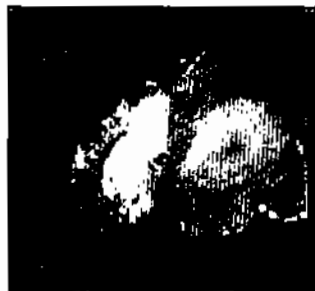Endoscopic re-evaluation 5 months later demonstrated polypoid mass in the corpus region.(Figure 1.b.)

Case II

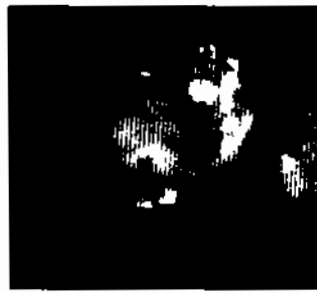A 53-year-old man was admitted for the fourth time in one month with the complaint of epigastric discomfort and fever. The pain was unrelated to meals. He also had black stools .



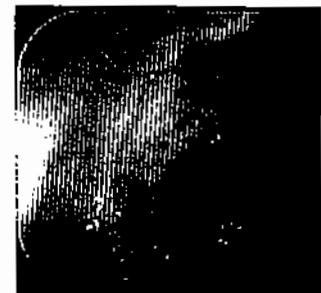
1.a



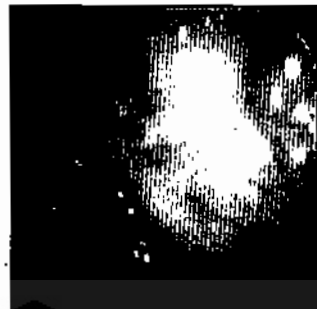
1.b



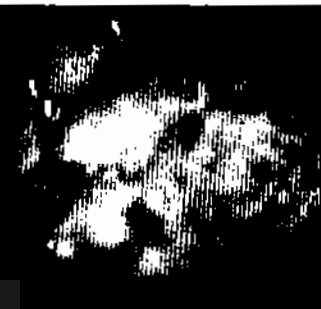
2.a



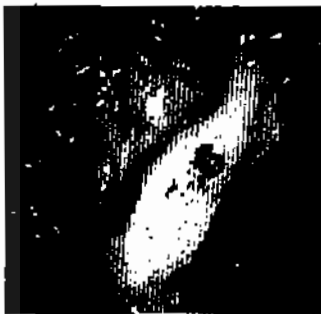
2.b



2.c



2.d



2.e

Figure 1. Gastroduodenoscopy showed an ulcer in the gastric cardiac region. The mucosa and fold were edematous and hyperemic (1a). Endoscopic re-evaluation 5 months later demonstrated polypoid mass in the corpus region.

ulcer in the gaster. Histopathologic examination demonstrated well-differentiated, low-grade lymphocytic malignant lymphoma. There was also *H. pylori*.

Two years later, the patient was hospitalized for hematemesis. Endoscopic evaluation demonstrated chronic active gastritis with erosion and (+) *H. pylori* findings (Figure 2.a). Histopathologic examination proved no malignant cells. Endoscopic re-evaluation one month later proved to be within normal limits (Figure 2.b.).

Two months later, the patient was readmitted with melaena. Endoscopic examination at that time demonstrated hyperemic, edematous, rough gastric mucosa with active bleeding and edematous folds (Figure 2.c.).

Histopathologic examination demonstrated low-grade maltoma. No *H. pylori* was found.

Physical examination on the last admission showed the patient to be moderately ill, soundly alert, no anemia, no jaundice. The patient's blood pressure was 180/110 mmHg, his temperature was 38.5°C and his pulse rate was 100 beats per minute. No lymph nodes were palpable. Heart and lung examinations proved to be within normal limits. His abdomen was not enlarged, it

Figure 2. Endoscopic evaluation demonstrated: chronic active gastritis with erosions (2a), re-evaluation one month later proved to be within normal limits (2b), demonstrated hyperemic, edematous, rough gastric mucosa with active bleeding and edematous folds (2c). Endoscopic evaluation showed rough, edematous, hyperemic, fragile mucosa in the fundus region (2d) and after eradication (2e).

was soft, there was tenderness in the upper abdomen, digestive sounds were normal. His liver and spleen were not palpable. There was no edema or palmar erythema on the extremities.

Laboratory results were as follows: hemoglobin level 12.8%, leukocyte count 4300/mm³, LED 10 mm/hour, platelet count 108,000/mm³, hematocyte 36%, SGOT 65 U/l, SGPT 29 U/l, γ GT 143 U/l, alkaline phosphatase 224 U/l, total bilirubin 0.47%, albumin 2.6%, globulin

65 U/l, SGPT 29 U/l, γ GT 143 U/l, alkaline phosphatase 224 U/l, total bilirubin 0.47%, albumin 2.6%, globulin 6.0%, ureum 51 mg%, creatinine 2.5 mg%. Urine examination was within normal limits.

Endoscopic evaluation demonstrated rough, edematous, hyperemic, fragile mucosa in the fundus region. There was also an ulcer (Figure 2.d.). Histopathologic examination demonstrated findings similar to low-grade small cell maltoma. *H. pylori* was negative.

Endoscopic evaluation after eradication therapy of *H. pylori* demonstrated an ulcer in the corpus region (Figure 2.e.). Histopathologic findings demonstrated similar results and also found *H. pylori*.

Abdominal CT scan was found to be within normal limits.

Case III

A 46-year-old male was hospitalized with a complaint of hematoschezia and pain in the lower right abdomen. The patient also suffered weight loss. The patient had been hospitalized 3 weeks prior to that time due to epigastric discomfort, vomiting and black stools. Endoscopic examination demonstrated chronic gastritis.

Physical examination showed the patient to be moderately ill, fully alert, cachexic. The patient's blood pressure was 120/80 mmHg, his temperature was 37.4°C, and his pulse rate was 96 beats per minute. His conjunctiva were not anemic, and there was no sign of jaundice from his sclera. Heart and lung examinations proved to be within normal limits. There was a palpable mass in the right upper abdomen. His liver and spleen were not palpable. There was no edema or palmar erythema on the extremities.

Laboratory results were as follows: hemoglobin level 13.7%, leukocyte count 9700/mm³, LED 45 mm/hour, SGOT 10 U/l, SGPT 14 U/l, γ GT 24 U/l, alkaline phosphatase 107 U/l, serum albumin 5.5%, serum globulin 2.3%, LDH 288 U/L, CEA 0.9 ng/ml.

Colonoscopic findings demonstrated invagination and tumor of the transverse colon.

Histopathologic examination of the specimen taken during colonoscopy demonstrated chronic granulomatous colitis. There were no signs of malignancy.

Abdominal ultrasound demonstrated normal findings.

Thoracic x-ray was within normal limits.

At that time, the patient underwent laparotomy. Operation reports indicated invagination and tumor of the transverse colon. Histopathologic findings demonstrated low-grade small cell maltoma of the lymphocyte-plasmacytoid type.

DISCUSSION

The incidence of MALT, gastric and colon lymphoma has never been reported in Indonesia. Several reports state that almost one fourth of extra-nodal lymphoma is located in the gaster. Gastric lymphoma makes up 5% of all gastric malignancy cases and makes up 60% of all primary gastrointestinal lymphoma in the West and 40% in the Middle East. A study reported that there has been an increase in the identification of primary gastric lymphoma since 1983.¹⁶

The average age at the time of diagnosis ranged from 55 to 60 years old with a male:female ratio of 1.7:1.¹⁶

The most common complaint is abdominal discomfort. The complaint usually starts with piercing pain. Dull pain is usually found in cases of benign ulcer. There is anorexia and weight loss.¹⁷ Nausea and vomiting due to obstruction of the gastrointestinal tract is rarely found. During physical examination, a mass is usually palpable. These findings were found in one-third of all cases, and half of them demonstrated a positive guaiac test. Bleeding and perforation is rarely reported.¹²

In the first two cases, we identified gastric MALT from endoscopic examination.

In the first case, a 62-year-old male had been repeatedly admitted with recurring upper gastrointestinal bleeding for 7 years prior to diagnosis.

In the second case, a 53-year-old male complained of upper gastrointestinal tract bleeding for 3 years. In this case, *H. pylori* was found. Endoscopic evaluation after eradication of *H. pylori* demonstrated improvements, even though the eradication had failed.

Cogliatti et al reported that primary gastric lymphoma is most commonly found in the antrum or pre-pyloric gastric region (58% of all cases), followed by corpus (28%) and fundus (1%). Endoscopic findings could take the form of a gastric ulcer, gastric cancer or hyperplastic gastritis. There is no endoscopic finding unique to this case.¹⁸ Kolve M et al stated that careful analysis of clinical symptoms and endoscopic examination could assist the diagnosis of non-Hodgkin primary or secondary gastric lymphoma. Secondary tumors are more commonly found in the fundus. Nevertheless, histopathologic examination is still required to differentiate between the two.¹⁹

In this case, we found an ulcer in the cardiac and corpus region, with a finding of chronic gastritis. Histopathologic examination demonstrated high-grade MALT lymphoma and one case of low-grade MALT lymphoma.

Regression from low-grade B-cell MALT gastric lymphoma through eradication of *H. pylori* was reported

by Wotherspoon et al in the year 1993,¹⁵ and Bayerdorffer et al.²⁰ Yoshkane et al reported one case of MALT gastric lymphoma in a 51-year-old male who underwent regression even though eradication of *H. pylori* had failed.²¹

The incidence rate of primary colon lymphoma makes up less than 1% of all colon malignancy²² and makes up 19-30% of all primary gastrointestinal lymphoma.^{23,24} The region most commonly inflicted is the caecum, followed by the rectum.^{24,25,26} Matsushita et al reported one case of lymphoma in the ileocaecal region in a 67-year-old female that resulted in intussusception.²⁷

In our case, we found invagination of the transverse colon detected through colonoscopy and established during operation. Histopathologic findings of the tumor tissue from the operation demonstrated small cell maltoma of the lymphocyte-plasmocytoid type.

Matsumoto et al reported regression of rectal MALT lymphoma after eradication of *H. pylori*,²⁸ which differed from the experience of Kim et al who reported that eradication of *H. pylori* failed to cure duodenal MALT lymphoma.²⁹

REFERENCES

1. Brandtzaeg P, Halstensen TS, Kett K, Krajci P, Kvale D, Rognum TO, Scott H, Sollid LM. Immunobiology and immunopathology of human gut mucosa. Humoral immunity and intraepithelial lymphocytes. *Gastroenterology*. 1989; 97: 1562-1574.
2. Cogliatti SB, Schmid U, Schumacher U, et al. Primary B-Cell Gastric Lymphoma: a clinicopathological study of 145 patients. *Gastroenterology* 1991; 101: 1159-1170.
3. Dawson I, Cornes J, Moson B. Primary malignant lymphoid tumours of the intestinal tract. *Br J Surg*. 1961; 49: 80-89.
4. Green JA, Dawson AA, Jones PF, et al. The presentation of gastrointestinal lymphoma: study of a population. *Br J Surg*. 1979; 66: 798-801.
5. Back H, Gustavsson B, Ridell B, et al. Primary gastrointestinal incidence, clinical presentation and surgical approach. *J Surg Oncol*. 1986; 33: 234-238.
6. Shani M, Modan , Goldman B, Brandstaeter S, Ramot B. Primary gastrointestinal lymphoma. *Isr J Med Sci*. 1969; 5: 1173-1177.
7. Wotherspoon AC, Ortiz-Hidalgo C, Falzon MF, Isaacson PG. *Helicobacter pylori*-associated gastritis and primary B-cell gastric lymphoma. *Lancet*. 1991; 338: 1175-1176
8. Sindelar WF. Cancer of the small intestine. In: De Vita VT Jr, Hellman S, Rosenberg SA, eds. *Cancer principles and practice of oncology*. Philadelphia; Lippincott; 1989: 889.
9. Tondini C, Giardini R, Bozzeti F, Vaagussa P, Santoro A, Bertulli R, et al. Combined modality treatment for primary gastrointestinal non-Hodgkin's lymphoma: the milan cancer institute experience. *Ann Oncol*. 1993; 4: 831-837.
10. Grody WW, Magidson JB, Weiss LM, et al. Gastrointestinal lymphomas. Immunohistochemical studies on the cell of origin. *Am J. Surg Pathol*. 1985; 9: 328-337.
11. Rosen CB, Van Heerden JA, Martin JK Jr, et al. Is an aggressive surgical approach to the patient with gastric lymphoma warranted?. *Ann Surg*. 1987; 205: 634-640.
12. Shim D, Dosortez D, Anderson T, Linggood R, Harris N, Wanfcc. Primary gastric lymphoma an analysis with emphasis on prognosis factors and radiation therapy. *Cancer* 1983; 52: 2044-2048.
13. Taal BG, Burgers JMV, Van Heerde P, Hart AAM, Somers R. The clinical spectrum and treatment of primary non-Hodgkin's lymphoma of the stomach. *Ann Oncol*. 1993; 4: 839-846.
14. Gospodarowicz M, Bush RS, Brown T. Curability of gastrointestinal lymphoma with combined surgery and radiation. *Int J Radioat Oncol Biol Phys*. 1983; 9: 3-9.
15. Maor MH, Velasquez WS, Fuller LM, Silvermintz KB. Stomach conservation in stages IE and IIE gastric non-Hodgkin's lymphoma. *J Clin Oncol*. 1990; 8: 266-271.
16. Wotherspoon AC, Doglioni C, Diss TC, et al. Regression on primary low grade B-cell gastric lymphoma of mucosa-associated lymphoid tissue type after eradication of *Helicobacter pylori*. *Lancet*. 1993; 342: 575-577.
17. Hayes J, Dunn E. Has The Incidence of primary gastric lymphoma increased? *Cancer*. 1972; 63: 2073-2076.
18. Mentzer SJ, Osteen RT, Pappas TN, et al. Surgical therapy of localized abdominal non-Hodgkin's lymphoma. *Surgery* 1998; 103: 609-614.
19. Kolve M, Fischbach W, Greiner A, Wilms K. Differences in endoscopic and clinicopathological features of primary and secondary gastric non-Hodgkin's lymphoma. *gastrointest. endoscopy*. 49 (3 Part 1) 1999: 307-315.
20. Bayerdorffer E, Neubauer A, Rudolph B, et al. Regression of primary gastric lymphoma of mucosa-associated lymphoid tissue type after cure of *Helicobacter pylori* infection. *Lancet* 1995; 345: 1591-1594.
21. Yoshikane H, Yokoi T, Hidano H, et al. Regression of superficial gastric MALT lymphoma with unsuccessful eradication therapy for *Helicobacter pylori* infection. *J. Gastroenterology* 1997; 32: 812-816.
22. Richards MA. Lymphoma of the colon and rectum. *Postgrad Med J* 1986; 62: 615-620.
23. Lewin JK, Ranchod M, Dorfman RF, et al. Lymphomas of the gastrointestinal tract: a study of 117 cases presenting with gastrointestinal disease. *Cancer* 1978; 42: 693-707.
24. Busch E, Rodriguez-Bigas MA, Barcos M, Petrenelli NJ: Primary colorectal non-Hodgkin's lymphoma. *Proceedings of the 46th cancer symposium of the surgical oncology*. Abstract P 124. Los Angeles 1993: 238.
25. Hwang W.S, Yao JCT, Cheng S-S, Tseng H-H. Primary colorectal lymphoma in Taiwan. *Cancer* 1992; 70: 575-580.
26. Burke RL, Mcyer PR, Gill PS, et al. Rectal lymphoma in homosexual men. *Arch Int med* 1986; 146: 913-915.
27. Matsushita M, Hajiro K, Kajiyama T, et al. Malignant lymphoma in the ileocecal region causing intussusception. *J. Gastroenterology* 1994; 29: 203-207.
28. Matsumoto T, Iida M, Shimizu M. Regression of mucosa-associated lymphoid-tissue lymphoma of rectum after eradication of *Helicobacter pylori*. *Lancet* 1997; 350: 115-116.
29. Kim JS, Jung HC, Shin KH, Song IS, et al. Eradication of *Helicobacter pylori* infection did not lead to cure of duodenal mucosa-associated lymphoid tissue lymphoma. *Scand. J. Gastroenterology*. 34 (2). 1999. 17-22.