

Role of CT in evaluating upper aerodigestive tract injuries

Sarita Magu, Kanupriya Agrawal, Vikas Kakkar

Abstrak

Studi ini bertujuan menilai peranan CT pada cedera saluran aerodigestif bagian atas. Dua puluh enam pasien dengan cedera saluran aerodigestif atas telah dievaluasi. Enam belas pasien mengalami trauma tumpul pada leher sementara 7 pasien mengalami luka tembus. Sebagian besar pasien datang berobat segera setelah mengalami cedera. Gejala yang timbul meliputi gangguan napas (14), nyeri leher (18), suara serak (7), batuk darah (2) dan kesulitan menelan (3). Cedera jaringan lunak terdapat pada 8 pasien, udem daerah ariepiglotik pada 4 pasien, hematoma ariepiglotik pada 1 pasien, udem pita suara (2) dan obliterasi sinus piriformis (5). Cedera daerah supraglotik terjadi pada 6 pasien, cedera glotis (8), dan subglotis (4). Cedera trakea terlihat pada 8 pasien yang terdiri dari pemisahan krikotrakea (1), robekan trakea (5) dan penyempitan trakea (4). Cedera hipofaring-esofagus terjadi pada 2 pasien. CT bermanfaat memastikan lokasi benda asing yang terjadi pada 2 kasus. CT juga membantu dalam mengambil keputusan pemilihan tata laksana pasien dan menghindari eksplorasi terbuka pada pasien dengan lesi mukosa minimal, fraktur stabil dan robekan tertutup. CT juga terutama bermanfaat untuk kasus-kasus dimana laringoskopi tidak bisa dilakukan. (*Med J Indones 2006; 15:81-9*)

Abstract

This study was aimed to assess the role of CT in upper aerodigestive tract injuries. Twenty six patients presenting with upper aerodigestive tract injury were examined by CT. Nineteen patients had blunt trauma to the neck while seven had penetrating injury. Most of the patients presented soon after injury. Symptoms included respiratory distress (14), neck tenderness (18), hoarseness (7), haemoptysis (2) and odynophagia (3). Soft tissue injuries were seen in 8 patients, aryepiglottic fold edema in 4, aryepiglottic fold haematoma in 1, vocal cord edema in 2 and pyriform sinus obliteration in 5 patients. Supraglottic injuries were seen in six patients, glottic injury in 8 patients and subglottic injuries in 4 patients. Tracheal injuries were seen in 8 patients and included cricotracheal separation (1), tracheal tears (5) and tracheal narrowing (4). Hypopharyngo-oesophageal injuries were seen in 2 patients. CT was helpful for localization of foreign bodies in 2 cases. CT is useful in deciding management of patients with upper aerodigestive tract injuries obviating the need of open exploration in patients with minimal mucosal injuries, undisplaced fracture and sealed tears. It is particularly helpful in cases when indirect laryngoscopy was not possible. (*Med J Indones 2006; 15:81-9*)

Keywords : Aerodigestive tract injuries, tracheal injuries.

Cervical aerodigestive tract is defined as the pharynx, larynx and cervical parts of the trachea and oesophagus. Injuries to the cervical aerodigestive tract are rare, with an incidence of one percent in blunt neck trauma and seven percent in penetrating neck trauma.¹

Management of acute laryngeal injury is based on the reconstitution of a stable skeletal framework and an intact epithelial lining. However, attention can be directed to therapy only after suspicion or diagnosis of laryngeal injury is made.²

The typical signs and symptoms of laryngeal trauma are cough, hoarseness, dyspnoea and stridor, cough, haemoptysis, cervical subcutaneous emphysema, loss of laryngeal prominence, cervical ecchymosis and haematoma and sometime cyanosis, retraction during respiration.³

Symptoms of oesophageal injury include dysphagia, haematemesis, hoarseness, and odynophagia.⁴

Although plain films are usually obtained, findings are nonspecific for prevertebral or mediastinal air, prevertebral soft tissue swelling, narrowed air column, or laryngeal cartilage fractures.⁵ CT provides the most objective evaluation regarding the extent of cartilage fractures and dislocations.⁶

Helical CT not only significantly reduces the time necessary to study the larynx, but enables one to perform multiple high resolution multiplanar reconstructions.⁷

METHODS

CT was performed in 26 patients with upper aerodigestive tract injuries including blunt trauma and penetrating injuries. Patients with corrosive poisoning and foreign body ingestion were excluded from the study. Patients were instructed to breath quietly during the study and not to swallow or cough during the study. Contrast enhanced CT scans of the neck were obtained using helical CT (a collimation of 5mm, table speed of 5mm and pitch of 1) with reconstruction at 2mm intervals: sagittal and coronal images generated or conventional CT (contiguous images with 5mm collimation) from the skull base to the thoracic inlet. The information obtained was correlated with the findings of direct laryngoscopy, indirect laryngoscopy and/or operative findings. CT scans of the cervical aerodigestive trauma patients (excluding cervical spine) were analysed in a prospective manner to evaluate its use as a diagnostic modality as well as to determine its contribution to patient management.

RESULTS

Of the 26 patients, 20 were men. The age range was 8-50 years. Nineteen patients presented with blunt trauma and 7 with penetrating trauma. Table 1 shows the mode of injury in the patients. The time interval between injury and CT is shown in Table 2. Table 3 shows the various symptoms and physical findings in these patients.

Plain x-ray of the neck revealed subcutaneous emphysema in 18 cases, airway narrowing in 5 cases, soft tissue oedema in 2 cases, and air fluid level in prevertebral space in one case.

Table 4 shows the site of injury as seen on CT. Table 5 shows the CT findings observed in upper aerodigestive tract injuries.

CT findings in cases with upper aerodigestive tract injuries

1. Soft tissue injuries including cricoarytenoid dislocations

We observed soft tissue injuries in 8 patients; 5 with blunt trauma and 3 with penetrating trauma. The soft

tissue injuries included aryepiglottic fold oedema (3 cases), aryepiglottic fold haematoma (2 cases), vocal cord oedema (2 cases), mucosal laceration (1 case), pyriform sinus obliteration (5 cases) and cricoarytenoid dislocation (3 cases).

Laryngoscopy performed in 2 cases suggested arytenoid dislocation which were confirmed by CT. In the third case, visualization of the interarytenoid area was obscured due to an adjacent soft tissue swelling. CT scan revealed anterior displacement of left arytenoid. In all 3 cases, the arytenoid was dislocated anteriorly.

2. Supraglottic injuries

In our series, we observed 2 cases with preepiglottic space oedema, 4 cases with fracture of the hyoid bone and 4 cases with fracture of the thyroid cartilage in the supraglottis (Table 6 and 7).

3. Glottic injuries

We observed 1 case with disruption of the anterior commissure, 4 cases with vocal cord injury, 5 cases with fracture of thyroid cartilage, 1 case with fracture of the cricoid cartilage and 4 cases with glottic narrowing (Table 6 and 7).

4. Subglottic injuries

We observed 1 case with fracture of the cricoid cartilage and 4 cases with subglottic narrowing (Table 6 and 7).

In our series we evaluated 7 patients with penetrating neck trauma by CT. Three of these cases had sustained stab injuries. CT was used to localise the foreign body, determine what path it followed in the neck and to direct further invasive studies (Table 7).

Tracheal injuries

Out of our 26 patients, 7 patients had tracheal injuries. The mode of injury in all cases was blunt injury including accidental strangulation in 3 cases, endotracheal intubation in 2 cases, being hit with an object in one case and history of fall in one case. CT revealed tracheal tears in 2 cases (Figures 1 & 2), tracheal tears and cricoarytenoid dislocation in 1 case, cricotracheal separation and tracheal tear in one case, tracheal tear with tear in the subglottic airway in one case, tracheal narrowing in one case, tracheal narrowing and a mucosal tag in the trachea in one case.

Table 1. Mode of injury in 26 patients

Mode of injury	No. of cases
Blunt	
Accidental strangulation	5
Hit with an object	3
Road traffic accident	4
Fall from height	3
Throttling	1
Suicidal hanging	1
Insecticide inhalation and intubation	1
Intubation	1
Total	19
Penetrating	
Stab wound	3
Fire arm injury	1
Road-traffic accident	1
Splitting stones	2
Total	7

Table 2. Time interval between injury and CT evaluation

Time interval	No. of cases
Blunt	
0-6 hours	8
6 hours - 24 hours	3
1 day to 3 days	2
3 days to 7 days	1
>7 days	3
Penetrating	
0-6 hours	5
6 hours - 24 hours	0
1 day to 3 days	1
3 days to 7 days	1
>7 days	1

Table 3. Symptoms and physical findings of patients with upper aerodigestive tract injuries

Symptoms	Blunt injury (n=19)	Penetrating injury (n=7)	Total (n=26)
Respiratory distress	10(52.6%)	4(59%)	14(56%)
Subcutaneous emphysema	13(68.4%)	5(70%)	18(69%)
Hoarseness	5(26%)	2(29%)	7(28%)
Haemoptysis	2(10.5%)	0%	2(8%)
Odynophagia	2(10.5%)	1(14%)	3(11%)
Neck tenderness and signs of external injury	11(58%)	7(100%)	18(69%)

Table 4. Site of injury as seen on CT in different modes of injury

Site of injury as seen on CT	Blunt injury	Penetrating injury	Total
Soft tissue injuries	5	3	8
Supraglottic	5	1	6
Glottic	4	4	8
Subglottic	3	1	4
Tracheal	7	1	8
Hypopharyngeal oesophageal	1	1	2

Table 5. CT findings in cases with upper aerodigestive tract trauma

CT findings	No. of cases
Soft tissue injuries	
A-E fold oedema	3
AE fold haematoma	2
Vocal cord oedema	2
Vocal cord haematoma	0
Pyiform sinus obliteration	5
Cricoarytenoid dislocation	3
Mucosal laceration	1
Supraglottic injuries	
Pre-epiglottic space oedema	2
Pre-epiglottic space haematoma	0
Fracture hyoid bone	3
Fracture thyroid cartilage	4
Glottic injuries	
Anterior commissure disruption	1
Vocal cord injury	4
Fracture thyroid cartilage	6
Fracture cricoid cartilage	1
Glottic narrowing	4
Subglottic injuries	
Fracture cricoid	1
Subglottic narrowing	4
Tracheal injuries	
Cricotracheal separation	1
Fracture tracheal rings	5
Complete transection	0
Tracheal narrowing	4
Hypopharyngo-oesophageal injuries	2
Others	2
Foreign body	1
IJV thrombus	2
Muscle haematoma	1
Fracture lateral pterygoid plate	1
SDH on CT head	

Table 6. CT findings in cases with laryngeal cartilaginous fractures

Mode of Injury	Symptoms	CT findings
Accidental strangulation	Neck-tenderness, respiratory distress, hoarseness	Displaced fracture thyroid cartilage, displaced hyoid bone fracture
Suicidal hanging	Respiratory distress, haemoptysis	Displaced fracture of thyroid cartilage
Stab injury	Respiratory distress	Undisplaced fracture of thyroid cartilage
Accidental strangulation	Respiratory distress	Fracture cricoid cartilage
Penetrating	Respiratory distress, hoarseness	Depressed fracture thyroid cartilage, fracture cricoid, vocal cord tear
Throttling	Swelling neck	Buckling of thyroid ala, vocal cord tear, IJV thrombus
RTA	Hoarseness	Displaced fracture thyroid cartilage, vocal cord tear
Splitting stones	Neck tenderness	Undisplaced fracture thyroid cartilage, vocal cord tear
Gunshot wound	Respiratory distress, cough, hoarseness	Undisplaced fracture thyroid cartilage
Penetrating	Pain	Fracture hyoid bone, fracture lateral pterygoid plate
RTA	Hoarseness, pain	Displaced fracture of thyroid ala, fracture hyoid

Table 7. CT findings in cases with penetrating neck injuries

Mode of Injury	Symptoms	CT findings
Stab	Respiratory distress	Anterior commissure disruption, subcutaneous emphysema
Stab	Respiratory distress	Fracture thyroid cartilage, mucosal laceration, glottic narrowing, subcutaneous emphysema
Road traffic accident	Respiratory distress, hoarseness	Fracture cricoid depressed, fracture thyroid cartilage, tear in vocal cord, subcutaneous emphysema
Splitting stones	Pain	Fracture thyroid ala, vocal cord tear, A-E fold haematoma, metallic foreign body in prevertebral space
Gunshot wound	Respiratory distress, cough, hoarseness	Fracture thyroid cartilage, haematoma false vocal cord, fire-arm track, subcutaneous emphysema
Splitting stones	Swelling	Foreign body obliteration of pyriform sinus, haematoma indenting airway
Stab	Odynophagia, neck tenderness	Collection with air fluid level in prevertebral space – scaled oesophageal perforation

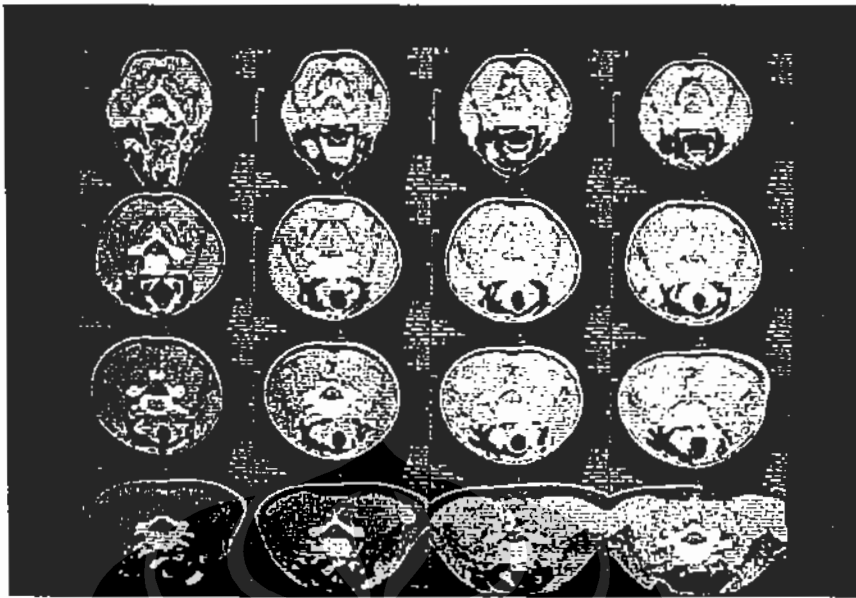


Figure 1. Serial sections from the upper trachea to the supraglottis showing tracheal tears with associated surgical emphysema.

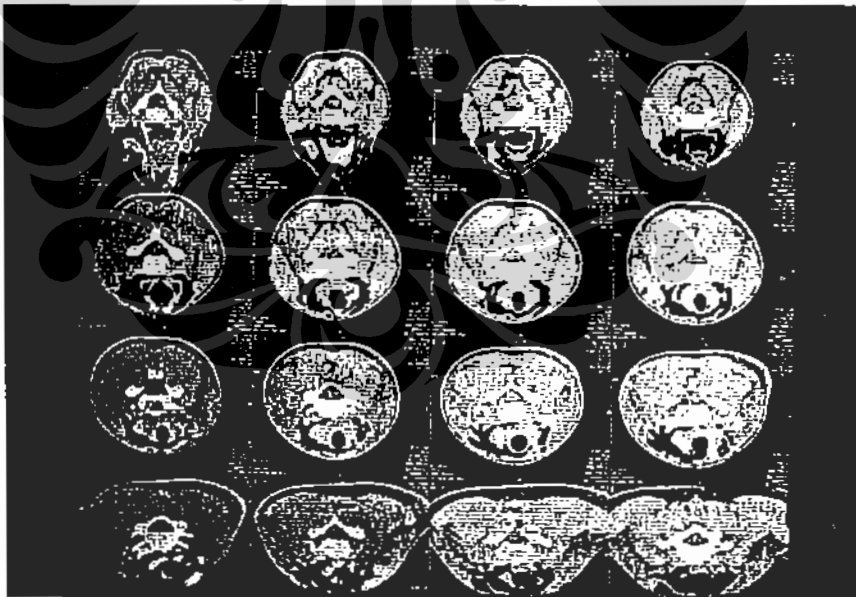


Figure 2. Sagittal MPR images showing the tracheal tears.

Paediatric cases

Out of 26 patients, 3 were in the paediatric age group. The mode of injury in all the cases was blunt injury. CT revealed a sealed tracheal tear, a mucosal tag in the trachea along with glottic narrowing and glottic and subglottic narrowing due to oedema in one case each.

Upper aerodigestive tract stenosis

We observed four cases who presented after more than 1 week of upper aerodigestive tract injury. All of these patients had respiratory distress. On CT subglottic and tracheal narrowing was seen in 1 case, glottic and tracheal narrowing was seen in 1 case and tracheal narrowing and hypopharyngeal oesophageal narrowing was seen in 1 case.

Hypopharyngoesophageal injuries

Two cases of hypopharyngoesophageal injury were evaluated by CT. The first case was a case of accidental strangulation following which tracheostomy have been done. The patient presented 4 months later with respiratory distress, odynophagia and regurgitation from the tracheostomy stoma. Barium swallow and CT showed hypopharyngeal narrowing. The second case was a patient of stab injury to the neck who developed odynophagia, neck tenderness and surgical emphysema. CT scan done 10 days after the injury revealed a collection with air fluid level in the prevertebral space in the neck and upper thorax with air tracking from a partially sealed oesophageal perforation.

DISCUSSION

Trauma to the larynx and trachea is relatively uncommon but potentially lethal injury, with mortality reported up to 20 percent in penetrating neck trauma and up to 40 percents in blunt trauma.⁸ The incidence of airway injuries in trauma is 0.03% to 1.5%.⁹ The mortality rates vary according to the location of injury and are higher for laryngotracheal dislocation and cricoid injuries (44%) compared with isolated tracheal injuries (25%) or laryngeal lesions (8%).¹⁰ Prompt diagnosis and treatment are essential for survival and decreased morbidity.

Injuries can be the sequelae of blunt trauma from motor vehicle accidents, sports injuries, strangulation

or penetrating injuries.⁵ Blunt injuries are caused by compression of the visceral compartment of the neck against the cervical spine by a collision with an object that is not sharp enough to penetrate the soft tissue. Penetrating injuries are caused by sharper objects.¹¹ In our series, 19 cases presented with blunt trauma to the neck and 7 patients with penetrating trauma. In our series also, most of the aerodigestive tract injuries were from strangulation, motor vehicle accidents and sports injuries. Of the patients with penetrating injuries, the majority were due to stab wounds and fire-arm injuries.

A large amount of subcutaneous air points to a laryngotracheal tear, whereas a small amount of subcutaneous air points to an oesophageal injury.³

CLASSIFICATION OF CT FINDINGS IN UPPER AERODIGESTIVE TRACT INJURIES

1. Soft-tissue injuries, including lesions of the cricoarytenoid joint

Soft tissue injuries include mucosal lacerations, oedema / haematomas of the aryepiglottic folds or vocal cords and obliteration of the pyriform sinuses which result in narrowing of the laryngotracheal lumen.¹²

CT accurately depicts the cross sectional area of the airway at all levels and does not over estimate the size of an irregular airway as conventional radiography occasionally does. In the acute phase, supraglottic swelling prevents a complete examination of the airway during direct or indirect laryngoscopy, making CT even more important.¹²

Dysfunction of the true vocal cords may be due to the mass effect caused by bleeding and oedema in the soft tissues.¹² Haematoma are located principally on the vocal cords but were sometimes observed on the false vocal cords or in the vallecula.¹³

Arytenoid Dislocation

Arytenoid dislocation results from severe laryngeal injury while lesser injury may result in arytenoid subluxation. The incidence of arytenoid subluxation or dislocation following trauma to the larynx is not known.^{14,15} In our series, the incidence was 12%.

Hoffmann et al¹⁶ observed that CT has been useful in identifying arytenoid subluxation and dislocation in cases in which endoscopic evaluation of the larynx is obscured by oedema and haematoma. In our study, also a similar observation was made. Arytenoid most commonly dislocates anteriorly as also observed by us (100%). Arytenoid dislocation is often accompanied by other laryngeal injuries.

Since indirect examination of the larynx is not always an easy procedure, the use of CT scan may provide help in making the diagnosis of arytenoid dislocation.

2. Supraglottic injuries

Supraglottic injuries are often associated with a fracture of the epiglottis or avulsion of the thyroepiglottic ligament. The base of the epiglottis may be displaced posteriorly and laceration of the thyroepiglottic ligament may cause bleeding and edema in the pre - epiglottic space which separates the epiglottis from the false vocal cords at the anterior commissure. Transverse and/or vertical fractures of the thyroid cartilage may be present, and the arytenoids may be displaced upward.¹²

In our series, we observed 2 cases with preepiglottic space oedema, 4 cases with fracture of the hyoid bone and 4 cases with fracture of the thyroid cartilage in the supraglottis.

3. Glottic injuries

Glottic injuries are usually heralded by a midline vertical fracture of the thyroid cartilage. The true vocal cords may be injured and the anterior commissure disrupted, and cricoid fractures may be present as well. While the arytenoid cartilages do not fracture as a rule, they often become dislocated at the cricoarytenoid joint. Most commonly they are shifted anteriorly, causing the true vocal cords to be shortened and moved in a paramedian direction and simulating paresis. Glottic dysfunction may be solely due to extensive soft tissue injury in the paralaryngeal space or at the anterior and posterior commissures.¹²

We observed 1 case with disruption of the anterior commissure 4 cases with vocal cord injury, 5 cases with fracture of thyroid cartilage, 1 case with fractured cricoid cartilage and 4 cases with glottic narrowing.

4. Subglottic injuries

Subglottic injuries are seen mainly as fractures of the cricoid cartilage and resultant airway narrowing. Because the cricoid cartilage is a ring, it must break in two places. The anterior fracture may be comminuted or simple, with posterior and lateral displacement of the fragments on both sides of the midline, in which case the cartilage may be thought of as "sprung apart" anteriorly or posteriorly.¹²

We observed 1 case with fracture cricoid cartilage and 4 cases with subglottic narrowing.

Injuries to the cricoid cartilage have a greater propensity for immediate airway compromise than injuries to the thyroid cartilage, as the full cartilaginous ring of the cricoid offers no room for expansion of subglottic haematomas³ as seen in two of our cases.

Penetrating neck injuries

Knife and gunshot wounds are primarily responsible for penetrating trauma. Injuries may vary from minor lacerations to severe disruption of the cartilage, mucosa, soft tissue, nerves and adjacent structures. Gunshot wounds are more likely than knife wounds to be associated with severe tissue damage.¹⁷

In our series we evaluated 7 patients with penetrating neck trauma by CT. Three of these cases had sustained stab injuries, 2 had hammer and chink injuries, 1 had a road-traffic accident and 1 had a gunshot wound. 3 of these had injuries from foreign body penetration into the neck. CT was used to localise the foreign body, determine what path it followed in the neck and to direct further invasive studies. Invasive studies could be eliminated from the diagnostic algorithm when CT demonstrated trajectories remote from vital structures.

5. Tracheal Injuries

Tracheal injuries are rare. Blunt trauma contributes to most tracheal injuries, predominantly involving the membranous portion of the intrathoracic trachea as a result of sudden increase in the intra airway pressure with a closed glottis at the time of impact. Penetrating injury is a less frequent cause of tracheal injury and more commonly involves the anterior extrathoracic trachea including the cartilages or the ligamentous portion between the tracheal rings.¹⁸

The most frequent site of injury is the anterolateral wall of the cervical trachea, perhaps because it is the most unprotected part. Hemoptysis, dyspnoea and subcutaneous emphysema of the neck are the most common symptoms and signs of penetrating tracheal injury.¹⁹

Laryngotracheal disruption comprises the rupture of the trachea just inferior to the cricoid cartilage or the first tracheal ring.

In our series, we observed 7 cases of tracheal injury. Among the 7 cases, 3 were due to accidental strangulation, 2 due to blunt trauma, 2 due to endotracheal intubation. Tracheal tear was seen in 5 cases, cricotracheal separation in 1 case and tracheal narrowing in 2 cases.

The paediatric larynx is injured less often than the adult larynx.²⁰ Children are less susceptible to blunt laryngeal trauma than adults because of the flexibility and mobility of the cartilage and larynx.²¹

In the present series all the 3 cases of paediatric laryngotracheal trauma sustained blunt injury to the neck. The child with laryngeal trauma may develop respiratory distress much more quickly than an adult because of the relatively small dimensions of the paediatric airway and the apparent propensity for children to develop oedema of the soft tissues of the larynx.² Significant respiratory distress was observed in a child with CT findings of glottic and subglottic narrowing due to oedema, and in a child with glottic narrowing and mucosal tag in the trachea.

Pharyngoesophageal injuries

Diagnosing esophageal injuries represents one of the most perplexing problems in patients with neck trauma.⁵ Approximately 10% of patients with penetrating neck trauma sustain pharyngoesophageal injuries.⁴ Blunt traumatic rupture of the esophagus is rare.²³ Physical examination is not reliable as a screening test because 25% to 30% of patients with pharyngoesophageal injuries are asymptomatic. Symptoms of oesophageal injury include dysphagia, haematemesis, hoarseness and odynophagia.⁴ Signs include subcutaneous air or crepitus, retropharyngeal air, retropharyngeal oedema, haematoma, deviated trachea and pneumomediastinum.⁴

The diagnostic studies currently utilized include barium swallow and endoscopy (flexible or rigid).⁵

Because CT scans are increasingly utilised in the diagnosis of penetrating and blunt neck injuries, it seems logical to use the information on the scans to screen for potential upper digestive tract injuries and select those patients who would most benefit from a more definitive evaluation.⁵

Scaglione et al reported CT findings of pharyngeal injury in blunt trauma.²⁴ In their retrospective review comparing CT to oesophagogram, slightly more than 50% of patients with documented minor lesions (less than 20 mm) had 7 to 20 mm of widening in the retropharyngeal space with or without air bubbles. All 13 cases with major pharyngeal lesions (greater than 20 mm), however had CT findings of significant gas and four had concurrent focal fluid collections in the retropharyngeal space.²⁴ Any leaks in the neck may result in a local abscess which can easily be drained without any catastrophic consequences.²⁵

Similarly, CT in penetrating trauma may demonstrate findings suspect for a visceral injury, such as focal extraluminal air in the region of the oesophagus and extensive subcutaneous air throughout the neck.⁵ Perhaps the most helpful sign is visualizing the trajectory of the penetrating trauma injury through the prevertebral region.⁵

Summary

Due to the excellent cross - sectional display of the anatomy of the upper aerodigestive tract, recognition of laryngeal cartilages in their various degrees of calcification and ossification, CT permitted an accurate description of the site and extent of injury. Multiplanar reconstruction (MPR) imaging done on multislice spiral CT permitted visualisation of the anatomy of the upper aerodigestive tract in coronal, sagittal and oblique planes. Surface Shaded Display (SSD) using multislice spiral CT allowed three - dimensional display of fracture dislocations. CT proved helpful in deciding the management of patients with upper aerodigestive tract injuries, obviating the need for open exploration in patients with minimal mucosal injuries / undisplaced fractures / sealed tears. It was useful in directing further studies and in confirming the need for open exploration in patients with moderate degree of injuries, such as displaced cartilaginous fractures, tracheal tears and oesophageal leaks.

REFERENCES

1. Vassiliu P, Baker J, Henderson S, Kathy A, Velmahos G, Demetriades D. Aerodigestive injuries of the neck. *Am Surg* 2001; 67: 75-9.
2. Larson DL, Cohn AM. Management of acute laryngeal injury: A critical review. *J Trauma* 1976; 16(9): 858-62.
3. Chagnon FP, Mulder DS. Laryngotracheal trauma. *Chest Surg Clin N Am* 1996; 6(4): 733-48.
4. Weigett JA, Thal ER, Snyder WH, Fry RE, Meler DE, Kilman WJ. Diagnosis of penetrating cervical esophageal injuries. *Am J Surg* 1987; 54: 619-22.
5. LeBlang SD, Nunez DB. Helical CT of cervical spine and soft tissue injuries of the neck. *Radiol Clin N Am* 1999; 37(3): 515-32.
6. Snow JB. Diagnosis and therapy for acute laryngeal and tracheal trauma. *Otolaryngol Clin N Am* 1984; 17(1): 101-6.
7. Alexander AE, Lyons GD, Fazekas May MA, Rigby PL, Nuss DW, David L, et al Utility of helical computed tomography in the study of arytenoid dislocation and arytenoid subluxation. *Ann Otol Rhinol Laryngol* 1997; 106: 1020-3.
8. Kelly JP, Watts RW, Moulder PV, Everson C, Burch BH, Lindsey ES. Management of airway trauma I: Tracheo-bronchial injuries. *Ann Thoracic Surg* 1985; 40: 551-5.
9. Sheely CH, Mattox KL, Beall AC. Management of acute cervical tracheal trauma. *Am J Surg* 1974; 128: 805-8.
10. Cicala R, Udsi K, Bults A. Initial evaluation and management of upper airway injuries in trauma patients. *J Clin Anaesth* 1991; 3: 91-8.
11. Templer JW. Trauma to the larynx and cervical trachea. In: Gerald M. editor. *Otolaryngology*. 1st ed. New York: Harper and Row; 1976:555-65.
12. Mancuso AA, Hanafee WN. Computed tomography of the injured larynx. *Radiology* 1979; 133: 139-44.
13. Kleinsasser NH, Priemer FG, Schulze W, Kleinsasser OF. External trauma to the larynx: classification, diagnosis, therapy. *Arch Otorhinolaryngol* 2000; 257: 439-44.
14. Peppard SB, Dickens JH. Laryngeal injury following short - term intubation. *Ann Otol Rhinol Laryngol* 1983; 92: 327-30.
15. Close LG, Merkel M, Watson B, Schaefer SD. Cricoarytenoid subluxation, computed tomography, and electromyography findings. *Head Neck Surg* 1987; 9: 341-8.
16. Hoffman HT, Brunberg JA, Winter P, Sullivan MJ, Kilney PR. Arytenoid subluxation: diagnosis and treatment. *Ann Otol Rhinol Laryngol* 1991; 100: 1-9.
17. Schaefer SD, Stringer SP. Laryngeal trauma. In: Byron J, Calhoun KH, Deskin RW, eds. *Head and Neck Surgery - Otolaryngology*. 2nd ed. Philadelphia: Lippincott - Raven; 1998:947-87.
18. Chen JD, Shanmuganathan K, Mirvis SE, Killeen KL, Dutton RP. Using CT to diagnose tracheal rupture. *Am J Roentgenol* 2001; 176: 1273-80.
19. Symbas PN, Hatcher CR, Boehm GAW. Acute penetrating tracheal trauma. *Ann Thorac Surg* 1976; 22(5): 473-7.
20. Shaefer SD. Laryngeal and esophageal trauma. In: Cummings CW, Fredrickson JM, Hawker LA, eds. *Otolaryngology Head and Neck Surgery*, 3rd ed. Philadelphia: Mosby; 1998:2001-12.
21. Fearon B. Acute airway obstruction. In: Ferguson C, Kendig, eds. *Otolaryngology*. 2nd ed. Philadelphia: PA Saunders; 1972:1183-213.
22. Myer CM, Orobello P, Cotton RT, Bratcher GO. Blunt laryngeal trauma in children. *Laryngoscope* 1987; 97: 1043-8.
23. Reddin A, Mirvis S, Diaconis J. Rupture of the cervical esophagus and trachea associated with cervical spine fracture. *J Trauma* 1987; 27: 564-6.
24. Demetriades D, Velmahos GG, Asenio JA. Cervical Pharyngoesophageal and laryngeal injury. *World J Surg* 2001; 25: 1044-8.