

The role of laparoscopic surgery in current treatment of endometriosis

Wachyu Hadisaputra

Abstrak

Tujuan tulisan ini adalah mendiskusikan tatalaksana terkini pengobatan endometriosis, dengan penekanan pada peran laparoskopi operatif dan pengobatan medikamentosa. Ketepatan mendiagnosis endometriosis tanpa Laparoskopi sangat lemah, dengan positif palsu 44 % dan negatif palsu 19 %. Tersangka endometriosis yang didiagnosis tanpa laparoskopi akan ditemukan 81 % secara laparoskopi, sisanya 19 % bukan endometriosis. Disimpulkan bahwa laparoskopi sangat dibutuhkan untuk mendiagnosis dan mengobati endometriosis. Pengobatan medikamentosa efektif dalam hal merendahkan progresifitas endometriosis. (*Med J Indones 2006; 15:121-4*)

Abstract

The objective of this paper is to discuss the current guidelines for treatment of endometriosis, emphasis on the role of laparoscopic surgery and medical treatment. The accuracy of diagnosis of endometriosis without laparoscopy is very low, as a false negative rate of 19 % and a false positive rate of 44 %, when a diagnosis was made pre laparoscopy, 81 % had the diagnosis can confirmed on laparoscopy, while 19 % did not have endometriosis. It is concluded that laparoscopy is required for evaluation and treatment of endometriosis. Medical therapy is effective in reducing progression of endometriosis score. (*Med J Indones 2006; 15:121-4*)

Keywords: endometriosis, laparoscopy, GnRH agonist, danazol, AFS score.

Endometriosis is defined as a present of glands and stroma of endometrium outside uterine cavity, the very recent studies concluded that viruses can detected in endometriosis lesion, in the other side the role of matrix metalloproteinase (MMPs), tumor invention metallo-proteinase (TIMP-1), progesteron, TGF β , macropage, natural killer cell surface receptors, IL 8, IL6, endometrial antibodies, Ca 19-9, P450m RNA aromatase and estrogen receptor widely believe can detected in endometriosis lesion.¹

Laparoscopy currently remains the only effective tool for the diagnosis and evaluation of endometriosis, and in Indonesia particularly recommended in patients with concurrent infertility. Diagnosis based on clinical examination alone is associated with a false-negative rate of 19% and a false-positive rate of 44%. Furthermore, unidentified and untreated endometriosis progresses 0.3 revised American Fertility Society (re-AFS) stage points per month. Given this gradual progression,

medical therapy, including long-term treatment, should be initiated in women with definitive evidence of endometriosis who need to maintain their reproductive potential. Gonadotropin releasing hormone (GnRH) agonists are recommended for the treatment of endometriosis-associated pelvic pain in younger women who wish to become pregnant at a later date, and in women in whom reproductive status is not a concern. Laparoscopy should be used in patients with endometriosis and infertility, while GnRH agonists should be used in patients with pelvic pain. However in the other side, the long term of GnRH agonists administration cause a high incidence of side effects; such as breakthrough bleeding, vasomotor symptoms, vaginal dryness, mood alteration, reversible reduction in bone mineral density (BMD) and diminished libido.²

Laparoscopy vs. clinical examination

Laparoscopy is used in the treatment of endometriosis to evaluate the clinical disease progression, identify the severity of disease and its localization, as well as for surgical treatment. Deep endometriosis lesions need to be detected and treated. Laparoscopy is a

Department of Obstetrics and Gynecology, Faculty of Medicine University of Indonesia / Dr. Cipto Mangunkusumo General Hospital, Jakarta, Indonesia

necessary tool for the diagnosis of endometriosis and is to date the only effective method of diagnosis.³

The clinical progression and/or exact stage and localization of endometriosis cannot be detected based on the incidence or types of painful sensation, i.e., painful symptoms. Pelvic pain was not an accurate indication of the stage and severity of pelvic endometriosis in 40% of patients. In cases of more severe, stage IV disease, some correlation was noted, however many severe cases reported no symptoms or less pain than patients with mild to moderate disease.⁴

Similarly, pelvic examination is not effective for evaluating the clinical progression, stage or disease localization. In patients with stage IV endometriosis, 32% showed no particular findings on pelvic examination. However, this method was effective in identifying immobility of the uterus in 32% and cul-de-sac nodules in 44% of patients with stage IV disease. It was less effective in patients with mild or moderate endometriosis. Many studies compared the localization of lesions, whether in the ovaries, cul-de-sac, rectal peritoneum, sacrouterine ligament or uterovesical pouch, as confirmed by laparoscopy, and the intensity of tenderness upon pelvic examination. Little relation was found between the lesions and the degree of tenderness.⁴

Extraperitoneal endometriosis and deep endometriosis can be identified by transrectal ultrasonography. This technique can be used to determine the thickness of the uterosacral ligaments, a common target of pelvic endometriosis. Patients with endometriosis on these ligaments have been shown to have thick and irregularly shaped uterosacral ligaments on transrectal ultrasound examination. The thickness of the ligaments was also associated with the clinical symptoms. Infiltrating endometriosis may therefore be detected using clinical transrectal ultrasonography, and laparoscopy is not necessary for diagnosis.⁵

An analysis of the accuracy of diagnosis comparing findings before and after laparoscopy indicated a false-negative rate of 19% and a false-positive rate of 44% if laparoscopy is not conducted. When a diagnosis of endometriosis was made pre-laparoscopy, 81% of the patients had the diagnosis confirmed on laparoscopy, while 19% did not have endometriosis. A negative diagnosis before laparoscopy was later confirmed in 56% of the patients but was positive in 44%.⁴

However, diagnosis of endometriosis based on clinical parameters without laparoscopy is unreliable regardless of the stage of disease. Laparoscopy revealed severe or moderate endometriosis in 30.4% of patients without an endometriosis diagnosis before surgery. Laparoscopy is therefore necessary to make the exact diagnosis and evaluate pelvic endometriosis.^{1,2,4}

Medical treatment

A retrospective study conducted by Japan group found that there was little relation between pregnancy rates in endometriosis patients, the AFS stages and medical or surgical treatment. Following diagnostic laparoscopy, 50% of stage IV endometriosis patients became pregnant compared to 27% of those with stage I disease. There was little relation between the pregnancy rate and the AFS stage and the therapeutic method used.⁶

Medical therapy with danazol or gonado-tropin-releasing hormone (GnRH) agonists, as measured by laparoscopy conducted at 6-month intervals, was found to be effective in slowing the progression in Re-AFS score.⁴ They performed a further study examining the effect of 6 months of treatment with leuprorelin on disease progression and found a reduction in disease severity as indicated by AFS score.

A study combining danazol with a GnRH agonist for 1 month showed a reduction in the gonadotropin flare associated with GnRH agonist monotherapy. Our group also compared the effect of 6 months of treatment with danazol 400 mg/day or a GnRH agonist on lesions and adhesions. Although the total scores were similar, a breakdown of the findings showed a 75% reduction in lesion score and a 25% reduction in adhesion score with the GnRH agonist, compared with 50% and 50% respectively, for danazol. While danazol and the GnRH agonist had the same effect on the total scores, danazol was more effective in treating adhesions and the GnRH agonist had a greater effect on the lesion scores.

Therapeutic guidelines for endometriosis

The Japanese Society of Obstetrics and Gynecology recently issued its treatment recommendations for patients with endometriosis and infertility with the

therapeutic goal of achieving pregnancy⁵ (Fig. 1). Laparoscopy or laparotomy is required to evaluate the endometriosis and determine the disease stage. Important factors include age and the severity of tubal adhesion scores. If severe tubal adhesion is observed, adhesiolysis is conducted, and if pregnancy does not ensue, assisted reproductive technology is utilized.

Laparoscopy is the first recommended treatment method for patients with pain. The evidence for the recommendation of oral contraceptives for pain is considered insufficient; however, based on a systematic review and meta-analysis, GnRH agonists

and danazol are recommended in the treatment of pelvic pain associated with endometriosis.^{1,2,6}

In summary, patients with endometriosis can be divided into four categories: 1) young patients with pelvic pain who desire future pregnancy; 2) patients with pelvic pain and infertility, 3) patients with infertility but no pain and endometriosis discovered on laparoscopy; 4) patients with pain who do not wish to become pregnant. Laparoscopy is useful in patients in categories 2 and 3 while treatments with GnRH agonists are a recommendable approach for women in categories 1 and 4.^{3,4,5}

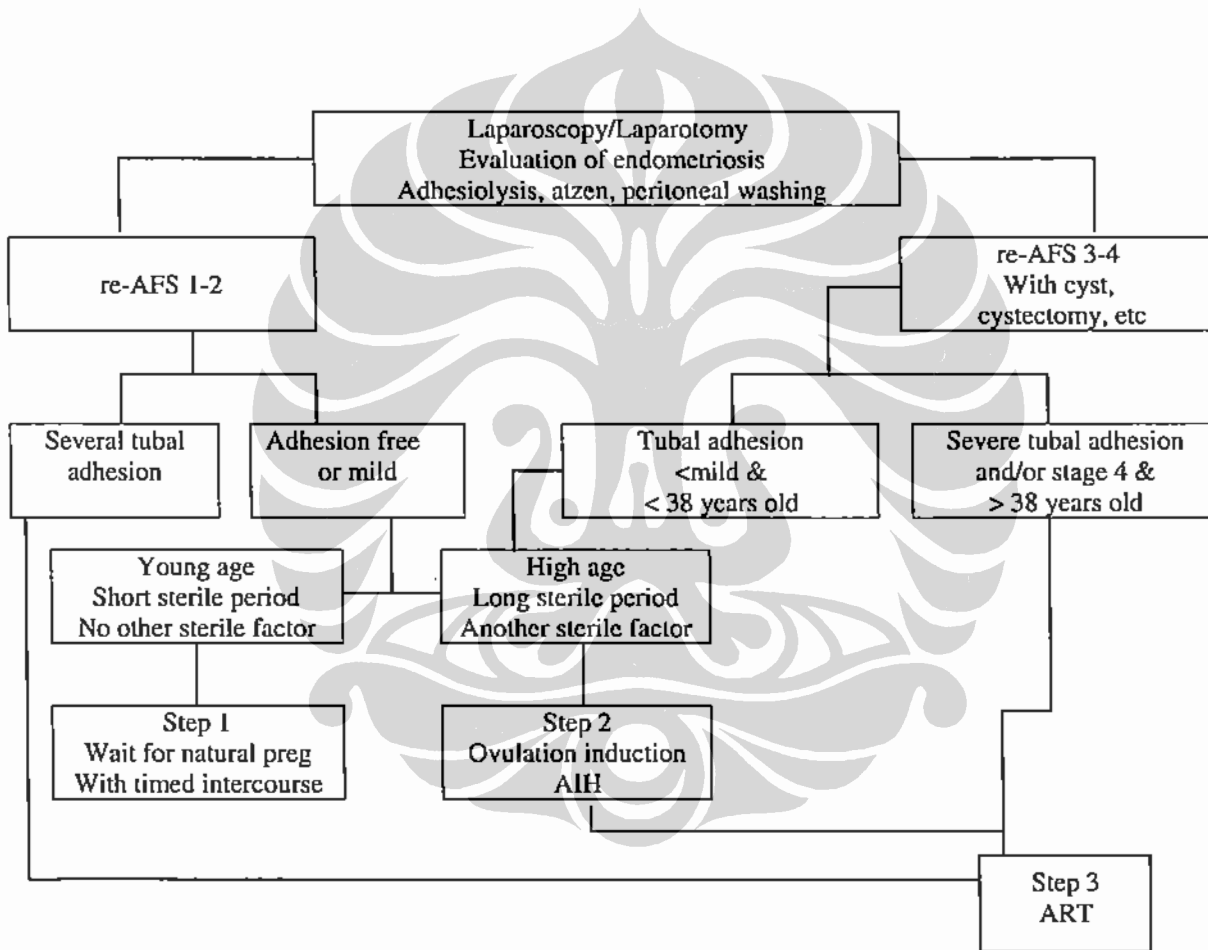


Figure 1. Japanese Society of Obstetrics and Gynecology therapeutic guidelines for endometriosis patients with infertility.³ Reproduced by permission.

CONCLUSIONS

1. Laparoscopy is required for the exact diagnosis and evaluation of endometriosis. If the disease is present but remains undiagnosed and untreated.
2. Medical therapy is effective in reducing progression of AFS score, however danazol is more effective on treating adhesions, while GnRH agonists have a greater effect on lesions.
3. Therapy with GnRH agonists without laparoscopy is one of the preferred treatments for patients with pelvic pain who do not wish for immediate pregnancy. Laparoscopy should be reserved for patients with infertility, while GnRH agonists should be used in patients with pelvic pain, despite the high false-positive and false-negative rates with diagnosis by clinical examination alone.

Acknowledgement

The author is indebted to Hiroshi Hoshiai, MD.PhD. best colleague from Japan who offered much idea in discussion of Endometriosis during expert meeting on

Endometriosis in The Asia Pasific Association of Gynecologic Endoscopy & Minimally Invasive Therapy (APAGE) congress in Hongkong on 27-29 December 2005.

REFERENCES

1. The Proceeding of expert meeting of Endometriosis, in The Asia Pasific Association of Gynecologic Endoscopy & Minimally Invasive Therapy (APAGE) congress, Hongkong, 27-29 December 2005.
2. Olive DL. The Role of Add back therapy in the United States. In *Drugs of today*, 2005. 41 (suppl): 23-26.
3. Hoshiai H. Women's Health Global Opinion Leaders Advisor Panel, Milan, March 9-10, 2005.
4. Fukaya T, Hoshiai H, Yajima A. Is pelvic endometriosis always associated with chronic pain? A retrospective study of 618 cases diagnosed by laparoscopy. *Am J Obstet Gynecol* 1993. 169(3): 719-22.
5. Ohba T, Mizutani H, Maeda T, Matsuura K, Okamura H. Evaluation of endometriosis in uterosacral ligaments by transrectal ultrasonography. *Hum Reprod* 1996. 11(9): 2014-7.
6. Hoshiai H, Ishikawa M, Sawatari Y, Noda K, Fukaya T. Laparoscopic evaluation of the onset and progression of endometriosis. *Am J Obstet Gynecol* 1993. 169(3): 714-9.