

# Clinical Manifestation and Management of Extra-Esophageal Gastroesophageal Reflux Disease

Juwanto \*, Chudahman Manan \*\*

\* Department of Internal Medicine, Faculty of Medicine, University of Indonesia/  
Cipto Mangunkusumo Hospital, Jakarta

\*\* Division of Gastroenterology, Department of Internal Medicine, Faculty of Medicine, University of  
Indonesia/Cipto Mangunkusumo Hospital, Jakarta

## ABSTRACT

GERD is a condition that gastric content go back into the esophagus. This condition could come disturbances in the respiratory tract, heart and otolaryng. Those extra-esophageal clinical manifestation are common but often miss our attention. So it is important to explore it further. The management of extra-esophageal GERD is similar with management of GERD. It is included life style modification and reducing refluxate with controlling pH with aggressiveness.

**Key Words:** Extra GERD, non cardiac chest pain, respiratory disturbance, omeprazole.

## INTRODUCTION

Wright, et al, evaluated 30 non-smoking asthmatic patients with symptoms of gastroesophageal reflux disease (GERD) confirmed by pH-Metry, the effect of 20-60 mg of omeprazole, 20 (67%) of which with improved asthmatic symptoms, and 6 (20%) with increased Peak Flow Rate (PFR).<sup>1</sup>

From the questionnaires distributed to 109 Canadians with asthma divided into 2 groups: the study subject and control group. In the study subjects with the following symptoms reported: 77% with heartburn, 55% with regurgitation, and 24% with dysphagia, the incidence of asthmatic attacks were more significant than in control subjects.<sup>2</sup> Since 1986, there have been many reported studies on the relationship between esophagus and non-cardiac chest pain. The relationship varies according to the study subject and diagnostic criteria. In 27 out of 30 patients (90%), chest pain did not indicate signs of ischemia.<sup>3</sup>

Extra-esophageal clinical manifestation of GERD are common, but often miss our attention. Thus it is important to analyze it further. This paper will discuss the anatomy, pathophysiology, clinical manifestation and management.

## ANATOMY AND HISTOLOGY

A physician who intends to diagnose and manage esophageal disorder should have knowledge of normal esophageal anatomy, pathologic changes during initial stages and optimal evaluation of each method for the evaluation of esophageal function and morphology.<sup>4</sup>

The adult esophagus is a flat muscular cylinder from the pharyngoesophageal junction (5<sup>th</sup>-6<sup>th</sup> cervical vertebrae) through the back of the mediastinum, ending on the gastroesophageal junction (first thoracic vertebrae). The esophageal cavity could distend as much as 2 cm to the front and back, and 3 cm to its sides. The length of the adult esophagus varies from 18 to 26 cm. The esophagus at the cervical region, from the pharyngoesophageal junction to the suprasternal point is approximately 4-5 cm. At this level, the esophagus is bordered by the front of the trachea, the vertebrae and the carotis and thyroid membranes at each side.<sup>5</sup>

The thoracic portion of the esophagus passes through the back to the tracheal wall and the back branch of the right aorta (Thoracic 4), and then to the branches of the trachea and the main bronchus, crossing the front of the aorta at the diaphragmatic hiatus. At the level of the 10<sup>th</sup> thoracic vertebrae, where the esophagus passes an open

space shaped like an ellipse on the diaphragmatic muscle and into the cardia of the gaster at an oblique angle.

At the level of the diaphragm, the esophagus is surrounded by elastic collagen fibers from the phrenoesophageal membrane.

### BLOOD FLOW<sup>8</sup>

The arterial blood flow to the esophagus is an extensive and overlapping segmental flow. The cervical portion receives its blood flow mainly from the inferior branch of the thyroid artery. Additional arterial branches are the carotid, vertebral, subclavic and ascending pharyngeal arteries.

The thoracal portion of the esophagus receives its blood flow from the right intercostal and the bronchial branches of the aorta. The abdominal portion of the esophagus receives its blood flow from branches of the left gangster and the lower left pricnicus artery.

We have adequate knowledge of the anatomy of the esophageal vein. The intraepithelial flow is collected into the sub-epithelial superficial venous plexus. This plexus flows into the intrinsic vein in the sub-mucosa.

### INNERVATION

The vagal nerve only innervates the esophagus parasymphatically, even though it brings a collection of sympathetic and parasympathetic fibers to the neck. The cervical portion of the esophagus is innervated from the recurrent laryngeal nerve innervate the upper tho-

racic esophagus. The left and right vagal nerves merge with sympathetic fibers to form the esophageal plexus.<sup>7</sup>

As they leave the esophageal plexus, the anterior and posterior vagal pathways separate. Below the diaphragm, the anterior vagal pathway branches into the hepatic and the anterior gastric branches. The posterior vagal pathway branches to the celiac plexus and the posterior gaster.

The esophageal wall consist of 4 layers: (1) the mucosa membrane, the tunica mucosa, (2) sub-mucosa or tunica sub-mucosa, (3) external muscle or tunica muscularis, (4) tunica adventia.

The inner most layer of the mucosal membrane is made up of non-keratinizing squamous epithelium, which supports the lamina propria tissue and the smooth muscle layer. The squamous epithelium is made up of basal cells as the basal stratum, the prichle cells known as the intermediate stratum and the superficial layer or the superficial stratum.

### PATHOPHYSIOLOGY

GERD could cause disturbances in the respiratory tract, heart and otolaryng through 2 chief mechanisms, as follows:

1. Gastropharyngeal reflux, with or without small aspirations from the gastric reflux matter causing an inflammatory reaction, known as the Crausaz reflux theory.<sup>9</sup>

The gastroesophageal reflux can usually be prevented by adequately functioning upper and lower esophageal sphincter. Even though gastric juices often passes through the lower esophageal sphincter, the basal pressure of the esophageal sphincter increases if the reflux causes increased pressure from the esophagologic to protect the respiratory tract from contact with reflux material. Swallowing or coughing could clear the reflux on the upper esophageal sphincter.

2. Stimulation of esophagopulmonary or esophagolaryngeal reflex, where reflux from the distal esophagus stimulate vagal reflex, causing bronchoconstriction. This theory is called the reflex theory.<sup>10</sup> Other mechanisms that play a role is the esophagobronchial reflex, an embryonic-derived portion of the common innervation. Other physiologic protection mechanisms prevent the reflux fluid from entering the larynx-pharynx space. This repellent and protective mechanism could mimic extra-esophageal symptoms found in GERD.

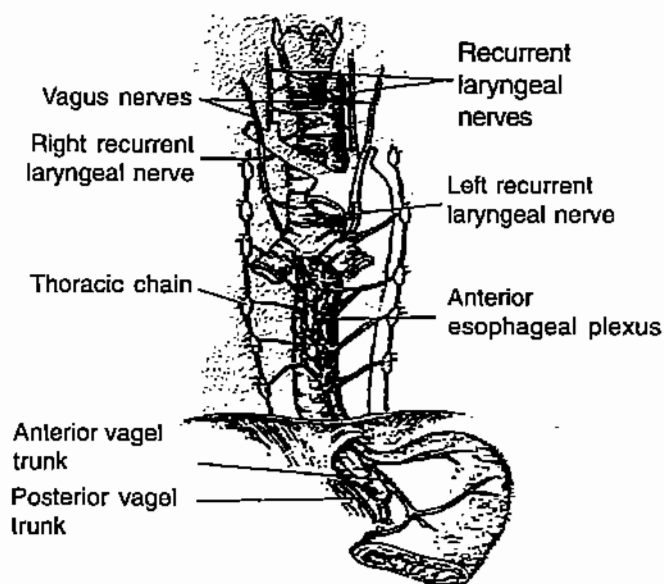


Figure 1. Esophageal innervation

The acidity of the lower esophagus could stimulate sensitive acid receptors, which would then interact with the vagal nerve on the upper respiratory tract. Administration of 0.1 N HCl into the esophagus demonstrates reduces respiratory flow.

In the mean time, very little is known about the afferent sensory mechanism in humans, which could cause chest pain, cough and asthma.<sup>11</sup>

This theory is supported by studies that demonstrates that small amounts of acid administered into the respiratory tract could cause bronchial spasm.

According to Gostal, acid reflux into the distal esophagus is commonly found in patients with asthma and chronic cough, but exposure on the proximal esophagus is rarely found, which supports the concept that acid exposure on the distal esophagus could cause the bronchial spasm reflex, while acid exposure on the proximal esophagus could cause chest pain.<sup>12</sup>

## CLINICAL FINDINGS

### Non-cardiac chest pain

Discomfort on the front chest is a fundamental part of the esophageal chest pain syndrome. The pain is illustrated as a burning sensation, located at the back of the chest, spreading to the back, neck, jaws, or arms, sometimes causing wind-like pain. The pain is usually unconnected with swallowing activities, but may be induced by cold or hot fluids. The pain usually awakens the patient from his or her sleep and gets worse if the patient is emotionally disturbed.<sup>11</sup> Patients with esophageal chest pain usually complain of other esophageal symptoms. For example, out of 100 patients, 74% suffered from pyrosis, 67% from regurgitation, 49% dysphagia, and 14% odinophagia, while 11% did not demonstrate esophageal symptoms.

Esophageal chest pain usually occur due to stimulation on chemical receptors (acid, pepsin, bile acid), mechanic receptors (distention, spasm), or thermal receptors (cold).

Long-term monitoring studies on the esophagus demonstrate that GERD is a direct cause of non-cardiac chest pain. In the year 1982, De Meester found a number of GERD patients from 24-hour esophageal monitoring. Twenty-three (46%) of 50 patients with angina-like chest pain were found with normal coronary angiograms.<sup>14</sup> DeCaestecker found abnormal reflux in 14 (28%) out of 50 patients with chest pain of unknown origin.<sup>15</sup> Schofield identified acid reflux in 23 (44%) out of 52 patients with chest pain and normal coronary angiogram,

but demonstrated reflux symptoms during treadmill test.<sup>16</sup>

Chest pain due to reflux could also occur in patients with coronary arterial disorder, which is difficult to diagnose. Out of 30 patients, 20<sup>67</sup> were found with chest pain accompanying acid reflux during long-term esophageal pH monitoring. Four patients also suffered from ischemia, 2 of which caused by acid and 1 with reflux.<sup>17</sup> It has been known that the differential diagnosis of chest pain is hard to determine. The unique symptom of angina pectoris may also be found in patients with chest pain due to esophageal disorders. This could be explained by the fact that the heart and esophagus has the same innervation.<sup>18</sup>

The diagnosis of GERD as a cause of non-cardiac chest pain is based on findings of esophagitis on endoscopy or pathological reflux on 24-hour esophageal pH monitoring. However, sometimes patients with esophagitis cannot be detected using endoscopy. Endoscopy has a sensitivity rate of approximately 50%, while 24-hour esophageal pH monitoring has a sensitivity rate of 80-85%. To increase the sensitivity, we could also use an index of esophageal symptoms such as pyrosis and regurgitation.<sup>19</sup> The algorithm as shown in Figure 1 could be used as guidance for the evaluation of chest pain.

Up to now, the "therapeutic trial" test using high doses of Proton Pump Inhibitors twice daily has been used. This is a sensitive, effective and cheap test to differentiate GERD from non-cardiac chest pain.<sup>20</sup> This study used 40 mg of omeprazole in the morning and 20 mg at night for 7 days.

### Respiratory tract disturbance

The cough reflex is induced by stimuli on the epithelial sensory nerve (cough receptor) on the tracheobronchial or laryngeal reflex branch complex transmitted to afferent nerves at the cough center in the brain stem, followed by stimulation of efferent nerves in the diaphragm, larynx, abdominal muscles and thorax to produce cough. GERD could also directly cause chronic cough due to stimulan of receptors in the trachea, larynx, and bronchus by aspiration fluid. It could also go through the esophagobronchial reflex, due to exposure of the acid-sensitive sensory nerves by reflux material. The vagal and superior laryngeal nerve receptor pathway could induce cough when stimulated by respiratory tract secretion, foreign bodies, or tumor.<sup>21</sup> Increased sensitivity of cough receptors could reduce the cough threshold. Such mechanism occurs if angiotensin enzyme inhibitors are used.<sup>22</sup>

GERD has been concluded to be able to cause chronic cough in 10-20% of patients. GERD is the third cause of

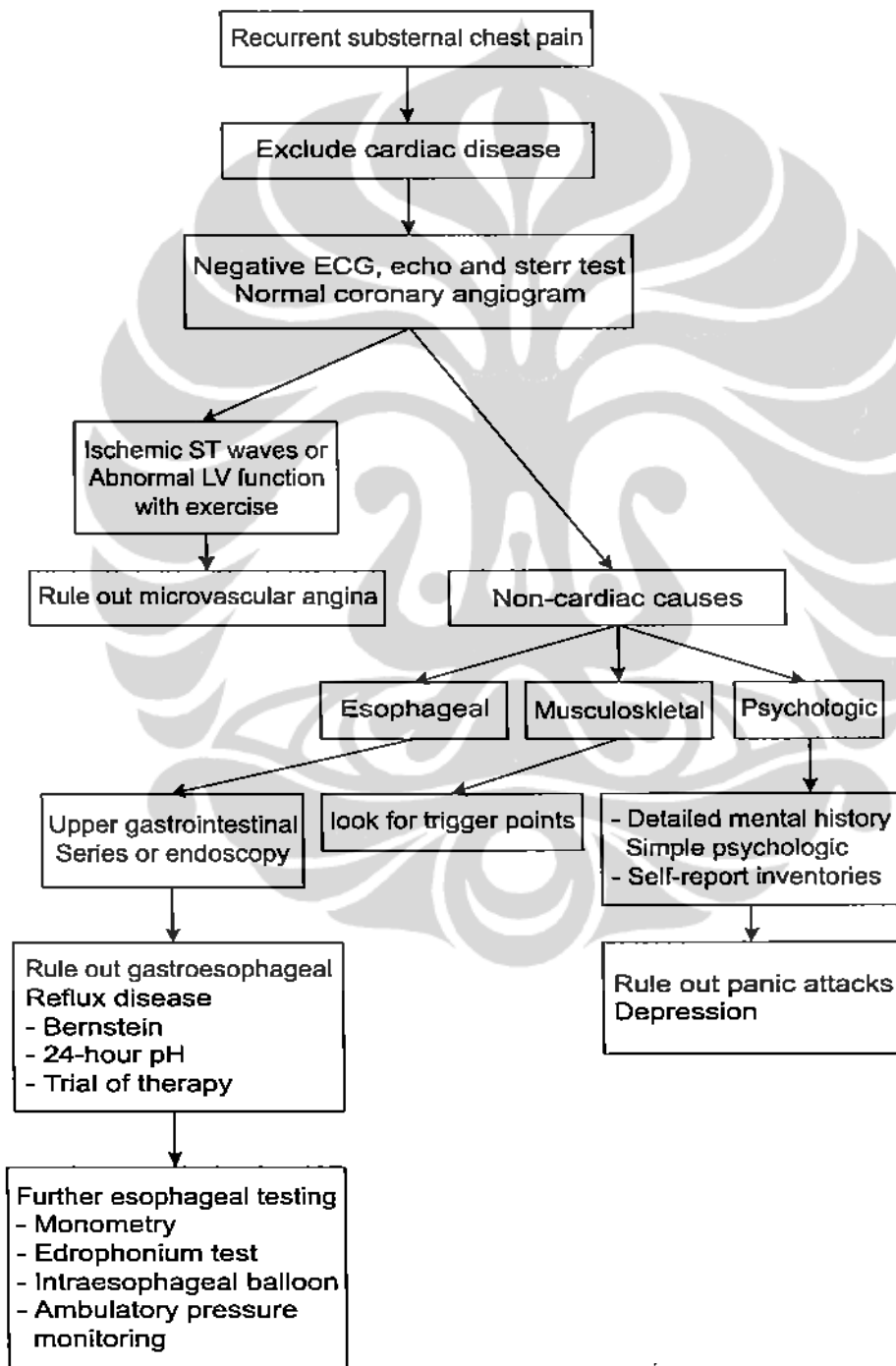


Figure 2. The algorithm of the evaluation of recurrent chest pain