

Colonic Tuberculosis: A High Index of Suspicion

Wulyo Rajabto*, M Usman SM*, Khie Chen**, Ari F Syam***,
Murdani Abdullah****, Djumhana A****, C Martin Rumende*****

*Department of Internal Medicine, Faculty of Medicine,

University of Indonesia/Dr. Cipto Mangunkusumo General National Hospital

**Division of Infectious and Tropical Disease, Department of Internal Medicine, Faculty of Medicine,
University of Indonesia/Dr. Cipto Mangunkusumo General National Hospital

****Division of Gastroenterology, Department of Internal Medicine, Faculty of Medicine,
University of Indonesia/Dr. Cipto Mangunkusumo General National Hospital

****Division of Hematology and Medical Oncology, Department of Internal Medicine, Faculty of Medicine,
University of Indonesia/Dr. Cipto Mangunkusumo General National Hospital

*****Division of Pulmonology, Department of Internal Medicine, Faculty of Medicine,
University of Indonesia/Dr. Cipto Mangunkusumo General National Hospital

ABSTRACT

Tuberculosis remains to be one of the most common problems in developing countries such as Indonesia. It can involve many organs including gastrointestinal tract. Colonic tuberculosis is an ancient disease and has long been recognized. However, it is sometimes difficult to make early diagnosis due to nonspecific sign and symptoms. In endemic areas, correct diagnoses were made only 50% of the time. Without a high index of suspicion of the disease, it has been rarely diagnosed correctly.

We reported a case of colonic tuberculosis in 18 years old female patient with lung tuberculosis. Endoscopic examination showed ulcerative mucosa, 'halo lesion', and pseudopolyp while PPD skin test, sputum smear and histopathological examination of endoscopic biopsy revealed negative for tuberculosis infection. The presence of lung tuberculosis had made high index of suspicion of colonic tuberculosis. Standard regimen of antituberculosis therapy was given and the patient showed good clinical response.

Keywords: high index suspicion, colonic tuberculosis

INTRODUCTION

According to World Health Organization (WHO), approximately one-third of the world population is under the risk of acquiring tuberculosis infection and more than 30 million deaths had been expected due to tuberculosis in the nineties, especially in Africa and Asia. Not surprisingly, there is also an increase in the percentage of patients with a typical extra-pulmonary forms of tuberculosis.¹

Tuberculosis (TB) remains to be one of the most common infection affecting patients in developing countries where poor sanitary conditions, over crowding, and malnutrition are easily found. It may involve any organ of the body, including the gastrointestinal tract. TB of the gastrointestinal tract is an ancient disease and has long been recognized since 1643. It can be primary from

ingestion of microorganism or secondary from pulmonary source.² The most frequent site involvement of gastrointestinal TB is the ileocecal region, even though any region of the gastrointestinal tract may be involved. Patients may complain of chronic abdominal pain, obstructive symptoms, weight loss, and diarrhea. An abdominal mass may be palpable. The PPD skin test may be positive or negative. Barium radiography may demonstrate mucosal ulcerations, thickening, or stricture formation. The diagnosis is established by either endoscopic or surgical biopsy. Treatment consists of standard anti tuberculosis drugs is effective.^{3,4}

Despite a high index of suspicion, gastrointestinal TB can be difficult to diagnose. Symptoms are vague, signs are non specific, and the disease mimics many other abdominal diseases. Presentation can be acute, acute on

chronic, or chronic and insidious. In endemic areas, correct clinical diagnoses are made only 50% of the time. Without a high index of suspicion, the disease is rarely diagnosed early.⁵

We report a demonstrative case of an 18 years old female patient, with colonic and pulmonary tuberculosis.

ILLUSTRATION

An 18-years old female was referred from polyclinic of hematology-oncology with microcytic anemia due to gastrointestinal bleeding. Three months before admission, she complained chronic non productive cough, fever, and night sweat. There was no history of hemoptysis. One month later, she had diarrhea 3-5 times daily with slightly black reddish stools for two months. She also complained colicky pain at right lower quadrant of the abdomen. One week before admission, she felt weak, fatigue, and had chest palpitation. She lost weight 6 kg within one month. She worked as sales promotion girl.

Physical examination revealed pale conjunctiva and no jaundice. The blood pressure was 120/70 mmHg, pulse rate 120/minute, respiratory rate 22/minute, and the body temperature was 36.5°C. She was 48 kg weight and 158 cm height. There were rales on the right chest. She also complained of right lower abdominal tenderness. There was no organomegaly or sign of ascites.

On admission, her hemoglobin level (Hb) was 7.8 g/dL with mean corpuscular volume (MCV) 68 fl (N: 80-100), white cell count was 9,600/ μ L, 67% segment and 26% lymphocyte, and platelet was 681,000/ μ L. Erythrocyte sedimentation rate (ESR) 42 mm/hour (N: 10-20), serum iron 26 μ g/dL (N: 60-160), TIBC 81 μ g/dL (N: 250-410), and ferritin level 260 (N: 13-150).

The problem on admission was chronic diarrhea and hypochromic-microcytic anemia. We administered NaCl 0.9% every 6 hours and new diatabs 2 tablets 3 times daily. The diagnostic plans are check complete blood count with peripheral blood film, routine urinalysis, analysis of feces with fecal occult blood test, colonoscopy and biopsy, and chest X-ray.

On the next day, the complete blood count showed hypochromic-microcytic anemia with Hb 7.2 g/dL and MCV 65.7 fl, leukocytosis with white cell count 13,200/mL, platelet 581,000/mL, reticulocyte 1.8% (N: 0.5 - 1.5), and erythrocyte sedimentation rate 14.0 (N: 0.0 - 20.0). Peripheral blood film showed hypochromic-microcytic with anisopoikilocytosis, ovalocyte, cell pencil, and polichromation. Routine urinary examination was within normal limit. Routine stool examination was positive for fecal occult blood test. Liver

function test, electrolyte, ureum, creatinin, and blood sugar level were within normal limit. The chest X-ray showed fibro infiltrate in the apex and the middle of the right lung which were highly suggestive for specific process.

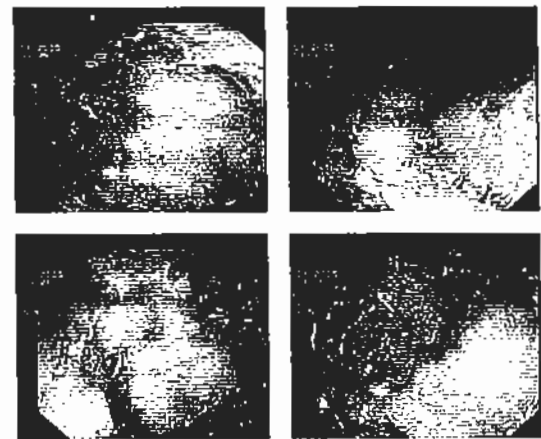


Figure 1. The colonoscopy suggested for colonic tuberculosis with differential diagnosis ulcerative colitis

The colonoscopy showed "Halo's Lesion" of descendents colon and transversum colon; small ulcer with hyperaemic mucosa, ulcerative mucosa with pseudopolyp on ascendens colon with friable and edema of mucosa; and caecum was not able to be evaluated. The conclusion of colonoscopy was ulcerative colitis of ascendance colon and pancolitis of descendance, transversum, and ascendance colon.

The colonoscopy suggested of colonic tuberculosis with differential diagnosis ulcerative colitis. The PPD skin test and acid fast bacilli examination were negative.

The problems in this patient were colonic tuberculosis, pulmonary tuberculosis with secondary infection, and hypochromic-microcytic anemia due to tuberculosis infection. We started to give anti tuberculosis drugs consisted of isoniazid 300 mg/day, rifampisin 450 mg/day, pyrazinamide 1,000 mg/day, ethambutol 1,000 mg/day, pyridoxine 10 mg three times daily, ceftriaxone 2 g once daily, administered blood transfusion of pack red cell, and symptomatic treatment. The complete blood count after transfusion revealed Hb level of 1.1 g/dL with MCV 73.0 fl, white cell count 8,100/ μ L, platelet count 443,000/ μ L, reticulocyte 1.5%, and erythrocyte sedimentation rate (ESR) 50 mm/hour.

One week later, the result of histopathology of colon revealed chronic inflammatory cells in the lamina propria due to infected colitis. After two weeks of hospitalization, the clinical condition was better and she was discharged from hospital.

Two months later, she weight gain 6 kg and there was no other complain except for non productive cough which

was improved much. The repeated chest X-ray showed improvement. Repeated acid stained fast bacillus examination was negative.

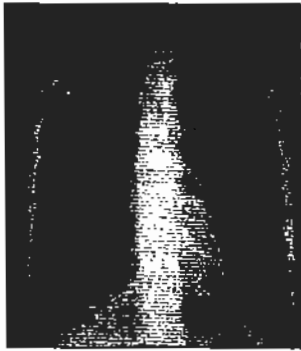


Figure 2. Chest X-ray showed fibro infiltrates

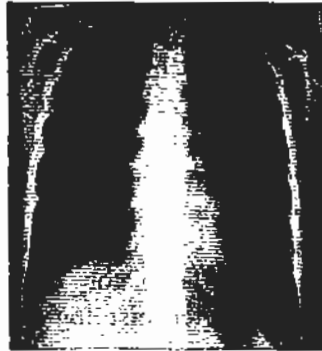

Figure 3. Repeated chest X-ray after treatment showed improvement

DISCUSSION

Colonic TB is a common disease in developing countries. TB of the gastrointestinal tract was once considered incurable.⁶ The annual incidence of TB is 1.8%, but the number of patients having primary or secondary intestinal TB is relatively low.⁷ In Indonesia, Simadibrata M observed that from 100 cases of chronic infective diarrhea, 3.6% was due to tuberculosis.⁸

The diagnosis of colonic TB in this patient was based on: history of chronic bloody diarrhea, colicky pain at right lower quadrant of the abdomen, fever and night sweat, weak, fatigue, and weight loss. From physical examination we only found right lower abdominal tenderness. Laboratory examination revealed: microcytic anemia, decreased serum iron and TIBC, high level of ferritin, feces analysis was positive for fecal occult blood test, and elevated ESR. The chest X-ray showed fibro infiltrat on the apex and the middle of the lung. The colonoscopy concluded: ulcerative colitis of ascendance colon and pancolitis. Histopathology of colon revealed chronic inflammatory cells in the lamina propria. Finally, after anti tuberculosis treatment were given, we found good clinical and radiological responses.

A combination of constitutional symptoms (fever, weight loss, and weakness), abdominal colicky pain, and alteration in bowel habits, with or without a palpable lump, suggested the diagnosis of gastrointestinal TB.⁹

A combination of constitutional symptoms (fever, weight loss, and weakness), abdominal colicky pain, and alteration in bowel habits, with or without a palpable lump, suggest the clinician the possibility of gastrointestinal TB.⁹

Misra et al reported the clinical features of 27 males and 23 females with colonic tuberculosis as follow:¹⁰

Table 1. Clinical Features and Laboratory Findings¹⁰

Symptoms and Signs	N	%
Abdominal pain	38	76
Anorexia	38	76
Fever	38	76
Weight loss	37	74
Diarrhea	28	56
Vomiting	18	36
Abdominal mass	14	28
Alternating diarrhea and constipation	7	14
Frank bleeding per rectum	5	10

On physical examination, abdominal tenderness is present in most patients. Additionally, a right lower quadrant mass is palpable 25-50% of the time.⁵ The predominant symptoms and signs of this patient were: fever, weak, fatigue, colicky abdominal pain, chronic bloody diarrhea, weight loss, and right lower abdominal tenderness. In extra pulmonary tuberculosis, patients usually present with constitutional symptoms (fever, night sweats, weight loss) and local manifestations related to the site of disease.¹¹ This patient had constitutional features: fever, weight loss, weak, fatigue and local (colon) features: colicky abdominal pain, right lower abdominal tenderness, chronic bloody diarrhea. Laboratory results of colonic tuberculosis can be non specific or normal. The most common abnormal laboratory finding is an elevated ESR and was documented in 90% of patients. Mild anemia was also relatively frequent. A positive purified protein derivative (PPD) test is found in 70-86% of patients.⁵ The laboratory findings of this patient were: microcytic anemia of chronic disease, leukocytosis, elevated ESR, and positive fecal occult blood test. Dwipayana P et al reported that lung tuberculosis was the most common etiology of anemia of chronic disease.¹²

Radiographic studies may be helpful, even though they are non specific. Evidence of active or inactive TB on chest X-ray supported diagnosis of colonic tuberculosis; however, a normal chest X-ray does not exclude the disease. Bhargava et al reported that only 35% of 29 patients with segmental colonic TB were diagnosed active or inactive pulmonary TB infection.⁵ Fortunately, this patient had specific appearance of TB infection on chest X-ray. Misra et al, reported 28% of patients with colonic tuberculosis showed positive chest X-ray.¹⁰ Kim YM et al also reported 39 cases of intestinal tuberculosis, 26 patients (67%) had active pulmonary tuberculosis confirmed by chest X-ray, sputum AFB smear, and culture.⁷ Barium studies are more useful supporting diagnosis of intestinal TB 66% of the time,

the most common findings on barium enema are a pipe stem colon and a cone shaped, retracted caecum. Other findings include a wide gap between a thickened ileocecal valve and a narrowed ileum (Fleischner's sign) and a fibrotic terminal ileum that empties into a rigid contracted caecum (Sterlin's Sign).⁵ Abdominal CT is useful in the diagnosis of intestinal tuberculosis even though again there are no pathognomonic findings. Many patients will have peripancreatic, portal hepatic, mesenteric/omental, or retroperitoneal adenopathy. Thickening of the bowel wall with associated adenopathy is commonly found.⁶

The value of colonoscopy to investigate intestinal tuberculosis has been reported. Adequate specimen for bacteriological and histological examination is highly suggested.¹³ As with most diagnostic procedures in intestinal tuberculosis, endoscopic findings are not pathognomonic. The ileocecal valve may be edematous or deformed. Occasionally, nodules of 2 to 4 mm in diameter or superficial ulcers can be found on the valve folds. These nodules tend not to be friable, although areas of ulceration can be observed between them. Pseudopolypoid folds and strictures have also been observed in patients with colonic tuberculosis. Ulcerations are the most common finding and are most frequently observed. The ulcers range from 2 to 3 mm to more than 3 cm in length, tend to be linear and superficial, and have irregular margins.⁶ The colonoscopy of this patient revealed: small ulcer associated with hyperaemic mucosa, ulcerative mucosa with pseudopolyp, friable and edema of mucosa, and stenosis/stricture. The colonoscopic features of colonic tuberculosis according to Misra et al consisted of ulcers (92%), nodules (88%), deformed caecum and ileocecal valve (42%), strictures (25%), multiple fibrous bands (8%), and polypoid lesions (6%).¹⁰ Kim YM et al, also reported colonoscopic findings observed in 42 intestinal tuberculosis patients: edema and hyperemia (100%), transverse or annular ulcer (93%), hypertrophic mucosa (31%), multiple erosions (12%), hemorrhagic spots (7%), luminal narrowing (5%), annular growing mass with ulcer (1%), fistula (1%), and stricture (1%).⁷ Those reports and colonoscopic appearance of our patient had showed that colonoscopy is a very useful procedure for making diagnosis of colonic tuberculosis.

The diagnosis of tuberculosis classically requires microbiological and culture confirmation of *Mycobacterium tuberculosis*, whereas, the diagnosis can be established histopathologically.¹ The histological features of tuberculosis are characteristic and similar in all sites of infection. The hallmark of active infection is

the necrotizing epitheloid cell granuloma. In epitheloid cell granulomata they are represented by macrophages, epitheloid cells, and giant cells of predominantly Langerhans type.¹⁴ Caseating granuloma are the most distinctive histologic finding in tuberculous enteritis, although in a number of patients, there may only be nonspecific changes in the bowel wall, with caseating granulomas restricted to regional lymph nodes. Other findings in tuberculous enteritis include ulceration, clusters of epitheloid cells that may be oval or spindle shaped, Langhans giant cell, and chronic nonspecific inflammation.⁶ The histologic features of this patient was chronic inflammatory cells in the lamina propria. Misra et al reported histological examination of the colonic biopsy specimens of colonic tuberculosis showed well-formed, non-caseating granulomas in 18%, collection of loosely arranged epitheloid cells in 40%, and chronic non-specific inflammatory changes in 42% of the patients.¹⁰ Shah et al also reported the diagnosis of tuberculosis was made histologically on colonoscopically taken mucosal biopsies in 40 of the 50 patients. Thirty seven of these 40 biopsy specimens showed areas of ulceration, the base of which contained loosely arranged small clusters of epitheloid cells beneath the granulation tissue. Langhans giant cells were also present in 24 and focal areas of caseation in 9 of total 40 biopsy specimens. These features were considered adequate to establish a diagnosis of tuberculosis. While 3 of biopsy specimens showed only chronic non-specific inflammation in the mucosal lamina propria.¹⁵

The management of all forms of abdominal tuberculosis hinges on chemotherapy. Standard regimens should be initiated promptly in proven or highly suspected cases. Precise histopathological diagnosis is difficult in many cases. If the clinical, radiographic, and endoscopic data were consistent with the diagnosis of colonic tuberculosis, and are adequate to rule out other common diseases, e.g. cancer, non-specific inflammatory bowel disease, and other specific infections, it is considered appropriate to give a 10 to 12 months trial anti-tuberculosis chemotherapy.¹⁶ This patient had clinical, radiographic, and endoscopy data consistent with the diagnosis of colonic tuberculosis eventhough the histopathological appearance of this patient only showed chronic inflammatory cells in the lamina propria (however, in colonic tuberculosis there may only be non specific changes in the bowel wall with chronic nonspecific inflammation), we might try to administer anti tuberculosis chemotherapy to this patient, and the clinical response is very good. Two months of anti tuberculosis therapy, she weighted gain 6 kg and there

was no other complains except non productive cough. The repeated chest X-ray showed improvement of active TB infection. An acid fast stained bacillus repeated examination of sputum smear was negative.

Anemia is a prevalent condition with a variety of underlying cause. Once the etiology has been established, many forms of anemia can be managed appropriately. Proper management of the patient with anemia requires a precise etiologic diagnosis.¹⁷ Anemia is common in patients with chronic inflammatory/infectious disease (anemia of chronic disease/ACD). The smear of ACD is mildly microcytic and hypochromic as the hemoglobin falls to level below 10 g/dL. The characteristic of serum iron studies show the typical pattern of low serum iron, low TIBC, and elevated serum ferritin level.¹⁸ The characteristic of anemia in this patient is anemia of chronic disease based on hypochromic-microcytic anemia as a result of hemoglobin was 7.8 g/dL with mean corpuscular volume 68 fl (N: 80-100). Iron studies revealed low serum iron 26 ug/dL (N: 60-160), low TIBC 81 ug/dL (N: 250-410), and elevated level of ferritin 260 (N: 13-150). Since the patient suffered from pulmonary and colonic tuberculosis, we thought that the etiologic agent of ACD in this case is tuberculosis infection.

The treatment of ACD is directed at the underlying disease. Iron therapy is of no benefit. If necessary, transfusion or erythropoietin therapy can be considered when the degree of anemia has caused cardiovascular problems. Severe anemia that is not expected to respond to either disease specific therapy or erythropoietin administration will need to be transfused. Younger patients will usually tolerate hemoglobin level of 7 to 8 g/dL although their exercise tolerance is relatively reduced. Transfusion can usually be scheduled at interval of weeks or even months.¹⁹ The etiology of anemia in this case had already been established, we decided to give pack red cell transfusion for this patient since she had reduced exercise tolerance.

REFERENCES

1. Uygur-Bayramicli O, Dabag G, Dabak R. A clinical dilemma: abdominal tuberculosis. *World J Gastroenterol* 2003;9: 1098-101
2. Naval GR, Chua ML. Diagnosis of intestinal tuberculosis among patients with chronic diarrhea: Role of intubations biopsy. *Phil J Microbiol Infect Dis* 1998;27:23-7
3. Leder RA et al. Tuberculosis of the abdomen. *Radiol Clin North Am* 1995;33:691
4. Raviglione MC, O'Brien RJ. Tuberculosis. In: Braunwald E, Fauci AS, Kasper DL, Hauser SL, Longo DL, Jameson JL, eds. *Harrison's. 15th ed. Principles of Internal Medicine.* McGraw Hill Med Pub Div. New York 2001.p.1024-35
5. Horvath KD, Whelan RL. Intestinal Tuberculosis: Return of an old disease. *Am J Gastroenterol* 1998;93:692-6
6. Field S, Lewis S. Intestinal and peritoneal tuberculosis. In: William NR, Stuart MG, eds. *Tuberculosis. 2nd ed.* Lippincott Williams & Wilkins. Philadelphia 2004.p.524-35
7. Kim KM, Lee A, Choi KY, Lee KY, Kwak JJ. Intestinal tuberculosis: Clinicopathologic analysis and diagnosis by endoscopic biopsy
8. Simadibrata M. Small bowel disease causing chronic diarrhea in Indonesian people. Thesis University of Amsterdam 2002
9. Dhar P. Abdominal tuberculosis. *Ind J Tub* 1998;45:9-12
10. Misra SP, Misra V, Dwivedi M, Gupta S. Colonic tuberculosis: Clinical features, endoscopic appearance, and management. *J Gastroenterol Hepatol* 1999;14:723-9
11. Harries A, Maher D, Uplekar M. *TB: A clinical manual for South East Asia.* World Health Organization 1997:32-44
12. Dwipayana P, Suega K, Dharmayuda TG, Bakta IM. Characteristics of anemia of chronic diseases in the Department of Internal Medicine, Sanglah Hospital Denpasar. Dalam: *Kumpulan Naskah Kongres Nasional dan Temu Ilmiah Perhimpunan Hematologi dan Transfusi Darah Indonesia (PHTDI) 2005.h.94*
13. Humphries MJ, Lam WK, Teoh R. Non-respiratory tuberculosis. In: Davies Ed. *Clinical tuberculosis.* Chapman & Hall Medical. London 1994.p.93-125
14. Sheffield EA. The pathology of tuberculosis. In: Davies Ed. *Clinical tuberculosis.* Chapman & Hall Medical. London 1994.p.43-54
15. Shah S, Thomas V, Mathan M, Chacko A, Chandy G, Ramakrishna BS, Rolston DDK. Colonoscopic study of 50 patients with colonic tuberculosis. *Gut* 1992;33:347-51
16. Iseman MD. Extra pulmonary tuberculosis in adults. In: *A clinician's guide to tuberculosis.* Williams & Wilkins. Philadelphia 2000.p.145-97
17. Little DR. Ambulatory management of common forms of anemia. *Am Fam Physician.* Available from URL: <http://www.aafp.org> (cited 4 August 2005)
18. Abramson SD, Abramson N. 'Common' uncommon anemia's. *Am Fam Physician.* Available from URL: <http://www.aafp.org> (cited 4 August 2005)
19. Hillman RS, Ault KA. Anemias associated with a reduced erythropoietin response. In: *Hematology in clinical practice: A guide to diagnosis and management.* 2nd ed. Mc Graw Hill, Med Pub Div. New York 1998.p.57-70

**PERPUSTAKAAN PUSAT
UNIVERSITAS INDONESIA**