

# Difficulties in Making Diagnosis of Inflammatory Bowel Disease: Several Cases Analysis

*Daldiyono Hardjodisastro, Ari Fahrial Syam*

Department of Internal Medicine, Faculty of Medicine, University of Indonesia/  
Dr. Cipto Mangunkusumo General National Hospital

## ABSTRACT

*Inflammatory bowel disease (IBD) is rarely found in clinical practice. However, the incidence of IBD seems to have increased recently. Generally, the patients will come to hospital with chief complaint of chronic diarrhea with or without hematochezia.*

*We reported two cases of IBD in which they had been misdiagnosed as colitis tuberculosis based on colonoscopy examination. Treatment of anti tuberculosis drugs had made no clinical improvement. Further evaluation suggested the diagnosis of IBD. They responded very well clinically after treated as IBD. This case report reminds us to consider the diagnosis of IBD in patient with chronic diarrhea and ulceration in colonic mucosa at colonoscopy.*

**Keywords:** *Chronic diarrhea, inflammatory bowel disease, hematochezia*

## INTRODUCTION

Inflammatory bowel disease (IBD) is a non-infective inflammatory disease of gastrointestinal tract and has intermittent clinical course. IBD is classified into two types: ulcerative colitis and Chron's disease. This classification is based on physical appearance and distribution of the lesions. IBD has always drawn attentions of gastroenterologists due to unpredictable clinical course, complications and treatment response. A part from that, it must be followed up in a long period of time.

IBD is rarely found in Indonesia. This is the reason why patient with IBD is often delayed in making diagnosis and giving appropriate treatment. Simadibrata et al reported 20% of 107 patients with non-infective chronic diarrhea were found to have IBD.<sup>1</sup> Early clinical presentations are fever, abdominal pain, diarrhea, weight loss, malnutrition, and intestinal bleeding. We might find anal fistula as first clinical manifestation of Crohn's disease. Unlike clinical feature of ulcerative colitis, we may also find abdominal mass in patients with Crohn's disease.<sup>2</sup> Endoscopic finding of IBD sometimes are quite similar to colitis tuberculosis which are ulcerative mucosa; fragile and hyperemic pseudopolyp. Beside

intestinal symptoms, we might find extra-intestinal manifestation of IBD such as fever, anemia, arthralgia, weight loss, visual disturbance and erythema nodosum.

Etiologic factors of IBD interact through a complex process and multifactorial. There are 4 factors related to etiologic mechanism of IBD e.g. persistent infection, damage of mucosal membrane integrity, dysregulation of immune response and dysbiosis of imbalance natural probiotics and pathogenic bacteria.

Appropriate treatment should be given after making diagnosis of IBD based on anamnesis, physical examination, laboratory results, endoscopic findings and histopathological examination. Pharmacologic therapy of IBD is given according to disease severity and site of lesions.<sup>1</sup>

## CASE REPORT

### Case 1

A Malay woman, whose age 57 years old was admitted hospital with chief complaint of chronic diarrhea since 2 months before. Frequency of defecation was 10-12 times per day. The stool was

liquid and no blood or mucus was found. She also had complaint of abdominal pain, nausea and vomiting. She had lost her weight of 10 kg in the last two months. She had been treated with sulfasalazine 3 x 500 mg/day, thiamphenicol 3 x 500 mg/day, fluconazole 1 tablet/day and made no clinical improvement.

Physical examination revealed signs of dehydration with decreased turgor and low blood pressure. The patient looked very weak and cachexia. Heart and lung examination were normal. Abdominal mass was not palpable.

Laboratory results were erythrocyte sedimentation rate of 34 mm/h, hemoglobin of 10.5 g/dL, leucocytes of 13,100/ $\mu$ L, hematocrit of 32%, platelet counts of 160,000/ $\mu$ L, BUN 23 mg/dL, creatinin 0.7 mg/dL, blood glucose of 104 mg/dL. Stool analysis found negative gram bacteria and fungus. Occult blood examination of the stool was positive. There was no acid fast-stained bacilli found in stool.

The patient was given intravenous fluid drip for rehydration and antibiotic of ceftriaxone 1 g/day. Serologic amuba test was negative. There was ankle edema and tachycardia during hospitalization. Abdominal ultrasonography revealed fatty liver. Upper endoscopy showed moderate erosive gastritis and duodenitis. Colonoscopy showed edematous, hyperemic and ulcerative rectosigmoid. Descending colon, transversum colon, ascending colon and caecum were hyperemic and edematous. Histopathological examination revealed erosive mucosa, edematous lamina propria and surrounded by acute and chronic inflammatory cells with plasma cells. Patient was diagnosed of IBD and treated with prednisone 1 mg/kg body weight and mesalazin 3 x 500 mg/day. In one month follow-up, she showed good therapeutic response and got clinical improvement.

## Case 2

A Javanese male patient, 57 years old was admitted to hospital with complaints of diarrhea and bloody stool. He also had abdominal pain and lost his weight. Colonoscopy showed ulcerative mucosa in caecum and intraluminal multinodule mass. The nodules were fragile and hemorrhagic. Pathological examination revealed non specific inflammation. Patient was treated with anti tuberculosis drugs. No clinical improvement observed during follow-up. Repeat colonoscopy showed polypoid mass at distal region of ascending colon and caecum border. Fragile and hemorrhagic mucosa. Pathological anatomy revealed edematous mucosa of caecum infiltrated by chronic inflammatory cells

lymphocytes, plasma cells and eosinophils. Lymph vessels were dilated. Mild crypta distortion and normal goblet cell population were found. There were no signs of malignancy. Histological examination suggested diagnosis of Crohn's disease. He was then treated with budesonide. Clinical improvement was shown in subsequent one month follow-up.

## DISCUSSION

Making diagnosis of IBD sometimes can be difficult due to non specific signs and symptoms which might be found in other gastrointestinal infection. On the other hand, IBD is rare among Asians and is more commonly found in Caucasians. However, diagnosis of IBD must also be considered in the presence of chronic diarrhea, weight loss, abdominal pain and bloody stool since IBD had also been reported in Asian people. Increasing case reports of IBD is not merely due to increased incidence but rather because of increasing awareness to have further evaluation in the possibility of making diagnosis IBD. This might also relate with the ability of pathologist to confirm diagnosis of IBD in suspected cases.

From the references, data indicated the incidence was no difference between male and female. Two peaks incidence of IBD were those aged 15-25 years old and 55-65 years old.<sup>4</sup> In this case report the patients were male and female and both were 57 years old.

In general, patients with ulcerative colitis come to hospital with chief complaint of diarrhea and weight loss. Usually there is no blood in stool. In this case report, both patients had diarrhea and weight loss. On the other hand, only one of them reported to have bloody stool. According to references, weight loss is commonly found among patients with IBD.

In the severe state of disease, patients could have fever, tachycardia and edema. Disease severity of IBD is also confined to high level of ESR more than 30 mm/h and low level of hemoglobin.<sup>3</sup> We also found similar clinical condition in one of patient in this case report.

Endoscopic examination to confirm diagnosis of IBD is not easy. There is no pathognomonic description for IBD. Endoscopic findings in IBD were not much different from those found in other kind of infective colitis. In Indonesia the incidence of tuberculosis have always been high, therefore, lesions suggested diagnosis of IBD must also consider tuberculosis as diagnosis differential. Intestinal tuberculosis are very much similar with Crohn's disease clinically and histopathologically. Site of lesions are caecum and ileum. If the chest X-ray revealed lung

tuberculosis, making the diagnosis of intestinal tuberculosis would be easier. The problem is that the lung is not always involved in intestinal tuberculosis.<sup>5</sup> In elderly, we also consider ischemic colitis as differential diagnosis of IBD.<sup>6</sup>

After the diagnosis of IBD was confirmed, adequate treatment should be given. In these two cases, treatment with mesalazine in the first case and budesonide in the second one could make improvement of symptoms effectively. In the management of IBD, pharmacologic therapy consists of general supportive therapy, symptomatic and specific therapy for IBD. Symptomatic therapy includes anti diarrhea, anti spasmodic and analgetics in accordance with symptoms of IBD that occur. Spesific therapy for IBD includes sulfasalazine, mesalazine, corticosteroids or imunomodulator such as azathioprine, 5-mercaptopurine, methotrexate and cyclosporine.

#### CONCLUSION

Case of IBD is rare among Asians, but this case report had drawn our attention and had proven that it might be possible to encounter IBD more frequently in Asia in the future. Apart from that, intestinal tuberculosis had been more frequently found. Thus, patient with symptoms of chronic diarrhea with or

without blood in the stool, abdominal pain and weight loss had always been considered intestinal tuberculosis as the etiologic cause. Ineffective treatment with anti tuberculosis drugs should make us consider diagnosis of IBD. Hopefully, these two cases could remind us that IBD might also be found among Asian people.



#### REFERENCES

1. Simadibrata M. Small bowel diseases causing chronic diarrhea in Indonesian people. Thesis University of Amsterdam 2002
2. Podolsky DK. Inflammatory bowel disease. *Engl J Med* 2002;347:417-29
3. Stenson WF. Inflammatory bowel disease. In: Yamada T, Alpers DH, Laine L, Owyang C, Powell DW (eds). *Textbook of Gastroenterology*, 3<sup>rd</sup> ed. New York: Lippincott Williams & Wilkins 1999
4. Calkins BM, Lilienfeld AM, Garland CF, Mendeloff AI. Trends in the incidence rates of ulcerative colitis and Chron's disease. *Dig Dis Sci* 1984;29:913
5. Chatzicostas C, Koutroubakis IE, Tzardi M, Roussomoustakaki M, Prassopoulos P, Kouroumalis EA. Colonic tuberculosis mimicking Chron's disease: case report. *BMC Gastroenterology* 2002;2:10-13
6. Reinus JF, Brandt LJ, Boley SJ. Ischemic diseases of the bowel. *Gastroenterol Clin North Am* 1990;19:319

Proton Pump Inhibitor LANSOPRAZOLE 30 MG

# PROSOGAN

**LIFE  
WITHOUT  
ULCER IS NOW  
POSSIBLE**



- ***Lebih cepat mengatasi keluhan dispepsia***
- ***Lebih cepat menyembuhkan ulkus***
- ***Lebih ekonomis***

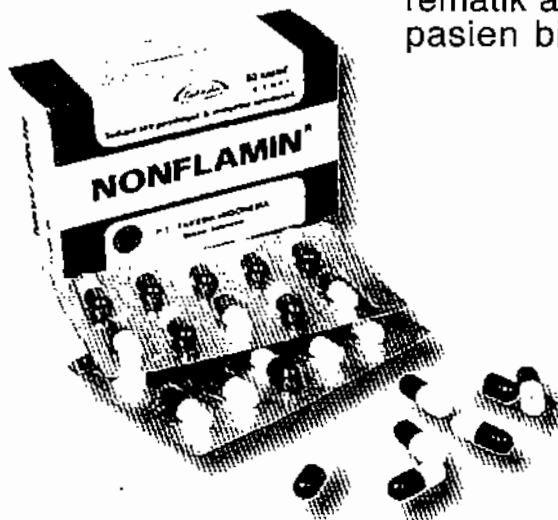

# NONFLAMIN

Antiinflamasi nonsteroid-tinoridin HCl

**ANTIINFLAMASI POTEN  
YANG BEREFEK ANALGETIK  
TERBUKTI PALING MINIMAL  
DALAM MENYEBABKAN ULKUS**

- **NONFLAMIN<sup>®</sup>** menyembuhkan peradangan akibat operasi gigi sehingga nyeri dan ngilu segera hilang, pasien dapat menikmati lezatnya makanan
- **NONFLAMIN<sup>®</sup>** adalah antiinflamsi pilihan yang dilengkapi dengan efek analgetik untuk menyembuhkan luka operasi dengan cepat
- **NONFLAMIN<sup>®</sup>** mengatasi peradangan kulit sehingga meningkatkan rasa percaya diri pasien
- **NONFLAMIN<sup>®</sup>** membantu mempercepat penyembuhan peradangan seluruh nafas atas sehingga pasien dapat bernafas dengan lega
- **NONFLAMIN<sup>®</sup>** memulihkan pergerakan pasien akibat peradangan dan nyeri rematik arthritis, dengan demikian pasien bisa bebas berolahraga



**Takeda**

Informasi lebih lanjut dapat diperoleh pada  
PT. TAKEDA INDONESIA